THE UNIVERSITY OF TEXAS
MD Anderson Cancer Center
Making Cancer History®

Neurosurgery Department

Cranial Section Featured Case

Resection of a Bifrontal Epidermoid Cyst

Brief History

This 47-year-old male patient presented with dizziness, headaches, and tingling in his legs. He had been having trouble speaking and finding the correct words in conversational speech. After almost fainting at work, he sought medical attention. A head CT scan completed at an outside hospital revealed a large, compressive mass on his brain involving both frontal lobes. He was then referred to MD Anderson. Subsequent brain MRI confirmed a large midline mass compressing the body of the corpus callosum and involving the bilateral frontal lobes. The lesion measured approximately 7 cm in maximal diameter and was multilocular/cystic in nature. We recommended a left-frontal craniotomy for resection of the mass with motor mapping.

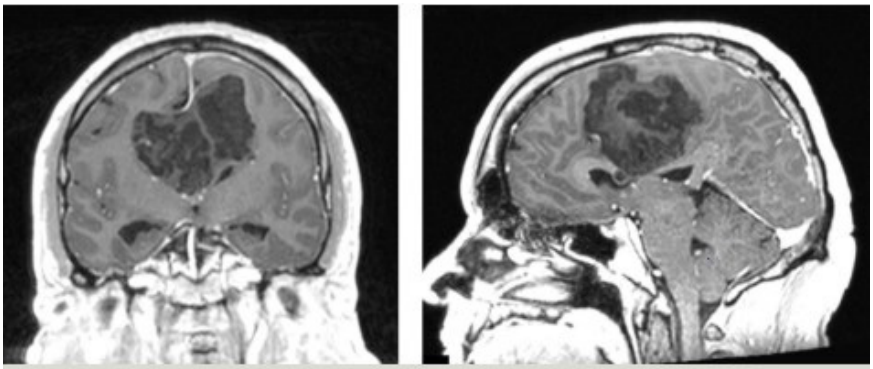

Preoperative Brain MRI

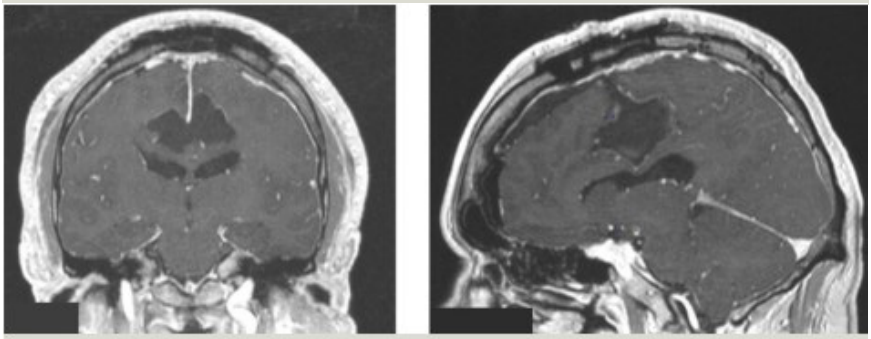

Post-operative Brain MRI

Procedure Details

The procedure was performed using the BrainSuite intraoperative MRI machine. After registration MRI was completed, anatomical landmarks were used to confirm our imaging registration and accuracy. The operation was begun with a 10-blade for skin incision. Subcutaneous tissue was elevated with Bovie cautery. The craniotomy was performed with multiple burr holes, which were connected with a high-speed drill, and the bone flap was carefully elevated from the underlying dura. The intraoperative ultrasound was brought into the surgical field and placed on the dura/brain surface to visualize the lesion in real-time. The cystic lesion was clearly visualized in the center of cranial opening. The dura was then opened, and the cortex was exposed.

The neuro-monitoring/neurophysiology service was called into the OR to assist with motor mapping. A cortical electrode grid was placed on the brain to locate the motor cortex and we confirmed it was a safe distance away from our planned cortical entry point. As safe entry was confirmed, we entered the left frontal lobe via the superior frontal gyrus. After deepening our cortical opening, we encountered the lesion, which was of mixed texture with a pearly white appearance. We resected the lesion on the left side first; multiple specimens were sent to pathology during this time. Once the left side of the tumor had been removed, we were able to tilt our trajectory to look to the contralateral (right) side and saw the remaining tumor in the deep right frontal lobe. We then resected the right sided portion of the lesion. At the base of the resection cavity, we visualized the anterior cerebral arteries, which remained good condition and the overlying pia was not violated.

Once we were satisfied with the extent of tumor removal, we performed an ultrasound to confirm that the lesion had been totally removed. The patient was then prepped and we performed an intraoperative MRI scan. Following the scan, we reviewed the images with the neuroradiologist who confirmed complete resection had been accomplished. We then turned our attention to hemostasis and closure. The dura was closed with running sutures and the bone flap was put back on with titanium plates and screws. The scalp and skin were closed with stitches and the head was wrapped in a bandage. Pathology confirmed the mass to be an epidermoid cyst.

The patient tolerated surgery well. His recovery from surgery was uneventful. After several days, he felt improved from his status before surgery. After two weeks, his incision was clean and dry, and sutures were removed. After several weeks, he was able to resume normal activities, including driving and returning to work.

Discussion

Epidermoid cysts are benign lesions. Occasionally, epidermoid cysts develop in the brain. Scientists believe that epidermoid cysts of the brain emerge during embryonic development. Epithelial cells—the cells that grow into skin and hair—become caught in embryonic brain tissue. Individuals may live many years with no symptoms. Epidermoid cysts make up between 0.2% and 1.8% of all intracranial tumors. They are considered to be of congenital origin and are very slow growing tumors. Although they are considered histologically benign, epidermoid cysts can cause neurological defects by compressing vital surrounding structures if they become large. Surgical resection can help alleviate symptoms. The Neurosurgery department at MD Anderson treats both benign and malignant brain lesions. We leveraged our expertise and technology to treat this patient, whose symptoms have now been alleviated.