Cancer
UT MD Anderson

Neurosurgery Department

Cranial Section Featured Case

Resection of a Large Third Ventricular Pilocytic Astrocytoma

Brief History

The patient, a 21-year-old left-handed male, presented at another hospital with significant headaches and sudden transient loss of vision. Imaging revealed a large, contrast-enhancing tumor in the third ventricle.The patient underwent an endoscopic biopsy at another hospital two years before coming to MD Anderson, and a ventriculoperitoneal shunt was placed to resolve hydrocephalus. Pathology was consistent with a pilocytic astrocytoma (PA). Subsequent scans indicated that the tumor was growing. The patient came to MD Anderson for a second opinion, and we recommended surgical resection, given that complete surgical resection of a PA can be curative.

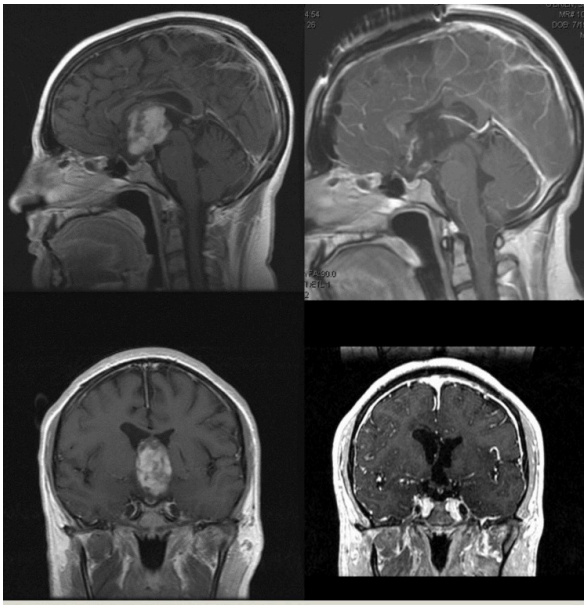

Preoperative MRI of the brain (top and bottom left) showed the visible pilocystic astrocytoma in the third ventricle. Post-resection (top and bottom right), there is no sign of tumor.The shunt is visible as an artifact.

Procedure Details

The surgical strategy was an interhemispheric, transcallosal, transforaminal approach aided by computer-assisted image guidance. The right-sided craniotomy was centered on the coronal suture and the sagittal sinus was exposed. The dura was opened and flapped medially, being careful not to over-retract on the sagittal sinus. We performed the interhemispheric dissection along the falx, first with loupes and then with the operating microscope.We separated the left and right cingulate gyri, exposing the glistening white the corpus callosum. The two anterior cerebral arteries wereidentified and separated. We then dissected through the corpus callosum, about 3 cm from front to back, opening into the frontal horn of the right lateral ventricle. Dissecting through the septum, we entered the frontal horn of the left lateral ventricle. Draining CSF allowed us to retract the right hemisphere more laterally and permitted a larger window into the lateral ventricle.

A grayish tumor mass was visible as it expanded and came through the right foramen of Monro. Medially, the fornix and the white matter coming around the foramen of Monro were visible. The choroid plexus was more posterior, laying over part of the grayish tumor.

We began by dissecting the edge of the tumor posteriorly. We coagulated the choroid plexus and opened the tela choroidea, which gave us access to the posterior part of the third ventricle. This offered access to the posterior and opposite portion of the tumor, which we followed around.We then dissected the anterior portion of the tumor. Both that portion and the tumor base were increasingly adhesive to the surrounding brain. Laterally, the tumor was essentially infiltrating the brain tissue.We performed a circumferential dissection of the tumor. After the initial dissection, we internally debulked the tumor with bipolar cautery and suction, as well as CUSA. As the tumor was internally debulked, we were able to dissect the tumor off the walls. We used the CUSA to protect the tissue

as it came off the wall, and we coagulated as minimally as possible.

Eventually, we reached the underside of the tumor at the floor of the third ventricle. We lifted the tumor off the floor, revealing arachnoid that gave us exposure to the top of the basilar artery. We then lifted the tumor out.At the end of the procedure, we felt that we had a complete resection of the tumor. We were looking at the floor and the basilar artery. We opened the arachnoid just in front of the basilar artery to create a third ventriculostomy and to open up CSF flow.Both foramen of Monro were wide open at the end of the procedure. We copiously irrigated with normal saline. The patient was valsalvaed on multiple occasions and there was no evidence of bleeding. Having completed the resection, we then slowly backed out our retractors.

Discussion

This complex operation was difficult because of the need to preserve the fornix—which was accomplished—and to remove the tumor from the wall of the ventricle.

The patient awoke able to follow simple commands, move all extremities, and with memory intact. He was brought to the intensive care unit awake. Pathology confirmed the diagnosis of a pilocytic astrocytoma, so he did not require chemotherapy or radiation. He has completed his college education and lives independently, supporting himself as a successful copyeditor. Follow-up visits have revealed no tumor recurrence after 11 years.