




## Thyroid Nodules: an Overview



Department of Endocrine Neoplasia and Hormonal Disorders

Making Cancer History<sup>®</sup>

**Naifa L Busaidy, MD**  
**Assistant Professor**  
**Department of Endocrine Neoplasia and Hormonal Disorders**



Thyroid nodules are a common problem found in up to two-thirds of the population on ultrasound examination. Nodules are often encountered incidentally on exams performed for other purposes. The prevalence increases with age and with radiation exposure and is higher amongst women. Approximately 5-15% of nodules are malignant; therefore, deciphering which nodules warrant attention is important. Factors that increase a nodules' likelihood of being malignant include: history of radiation exposure, male patient, age over 45 years and family history amongst others (Table 1).

A thyroid nodule is a discrete lesion seen within the thyroid gland that is distinct from the surrounding thyroid parenchyma. Thyroid nodules can be discovered on palpation or ultrasonographic examination or other imaging modalities (CT, MRI or FDG-PET scan etc). Nonpalpable nodules discovered by imaging modalities done for other purposes are often termed "incidentalomas".

### Workup of Thyroid Nodules

When the thyroid nodule is discovered, a complete history and physical examination should be performed. A pertinent history should include: history of thyroid disease, history of thyroid cancer or thyroid cancer syndromes (familial polyposis, cowden's, carney's, multiple endocrine neoplasias), and hoarseness. On physical exam, one should note the size of the thyroid and the nodules, associated lymphadenopathy, associated fixation of nodules to surrounding structures, signs of thyrotoxicosis and vocal cord paralysis.

### Laboratory and radionuclide investigation

Once thyroid nodules are discovered, a serum TSH should be checked. If the serum TSH is suppressed, then a radionuclide thyroid scan is performed to determine if the nodule of interest is a "hot" nodule. Radionuclide scans include either technetium <sup>99m</sup>Tc pertechnetate scans or <sup>123</sup>I scans. "Hot" nodules are in-

dicative that the nodule is hyperfunctioning and tracer uptake is greater than the surrounding normal thyroid. Given that "hot" nodules rarely harbor malignancy, biopsy of these nodules is not usually warranted. Treatment for thyrotoxicosis should then ensue.

**Table 1: Patient and Nodule Characteristics with increased likelihood of nodule malignancies.**

<b>Nodule Features that increase risk of malignancy</b>
15 > age > 45 years
Male Sex
History of childhood radiation
History of ionizing radiation exposure
Family history of MTC/MEN2
Nodule > 4cm
High risk ultrasound features
FDG-uptake in nodule
BRAF, RET/PTC, RAS, PAX8-PPARγ mutations

If the nodule is cold, an ultrasound of the neck with a fine needle aspiration is performed of the suspicious appearing nodules. A "cold" nodule in and of itself does not indicate malignancy, as 85% of cold nodules are still benign.

If the TSH is normal or elevated, no radionuclide imaging is necessary.

(continued on Page 2)

### Table of Contents

Thyroid Nodules: An Overview	Page 1
Upcoming Events	Page 2
The Thyroid Nodule Clinic	Page 3
The Combined Role of Ultrasound and Ultrasound Guided Fine Needle Aspiration of Thyroid Nodules: The MDACC Experience	Page 5
Robotic Surgery for the Thyroid	Page 6
Recent News from the Endocrine Team	Page 7

(Busaidy, continued from Page 1)

Other laboratory investigations including serum thyroglobulin and calcitonin are not commonly performed in the workup of the thyroid nodule, but this is an area of controversy amongst the various thyroid nodule guidelines. The exception to this is the measurement of serum calcitonin in patients suspected of having medullary thyroid carcinoma or multiple endocrine neoplasia type 2.

#### Ultrasound

Ultrasound imaging should be performed on all patients with suspected thyroid nodules. This includes patients with incidentally found nodules on other imaging or palpation. (See accompanying article "The Combined Role of Ultrasound and Ultrasound Guided Fine-Needle Aspiration of Thyroid Nodules: The MDACC Experience").

Fine Needle Aspiration (FNA) should be performed on any sonographically suspicious nodules and any abnormal lymph nodes. In general, FNAs under ultrasound guidance are preferred over palpation guided FNAs. The ultrasound should be done by those well-skilled in the ultrasound of the thyroid and neck.

Some features that indicate suspicion of malignancy include: poorly defined margins, irregular shape, presence of microcalcifications, hypoechogenicity, solid nodules and chaotic intranodular vascularity among others. There is much controversy about using size as a criterion for FNA, as nodule size itself is not predictive of risk of malignancy.

Description of nodules within a multinodular gland may help determine prioritization for FNA of particular nodules. Ultrasound elastography and contrast media may be a helpful adjunct in the future for determining which nodules are more likely to be malignant.

#### Cytology

Cytopathologists should be well versed with reading and interpreting cytology on thyroid nodules. Thyroid nodules can be classified into one of the following cytologic categories: nondiagnostic, malignant, benign, and indeterminate. Per the recent NCI state of the art conference on thyroid nodules, indeterminate can include: suspicious for malignancy (risk of malignancy 50-75%), follicular lesion of undetermined significance (risk of malignancy 5-10%), follicular or hurthle cell neoplasm (risk of malignancy 15-25%) and atypical cells of undetermined significance.

These categories are very helpful in the discussion with the patient and the decision and planning for surgery.

#### Treatment

##### *Nondiagnostic:*

Nodules that yield nondiagnostic cytology warrant repeat ultrasound guided FNA, as this procedure will yield a diagnostic cytology in 50-

75% of nodules. Nonetheless, repeat FNA is often done at 3-6 months after initial FNA to increase diagnostic yield. If the repeat FNA yields nondiagnostic results, it may be prudent to consider surgery in order to facilitate diagnosis.

##### *Benign Nodules:*

Benign lesions are often observed without surgery. Exceptions to this include a progressively growing nodule, a symptomatic nodule, or a patient's preference. Observation includes repeat ultrasound (noting changes in size and characteristics) in 6-18 months with intermittent follow-up thereafter, perhaps at 3-5 year intervals. It is not recommended to use levothyroxine to attempt to shrink the nodules.

##### *Malignant Nodules and Suspicious for Malignancy:*

Nodules positive for malignant cytology or suspicious for malignancy at FNA are recommended to undergo surgery. The extent of surgery is controversial, based on patient history, nodule size and lymph node status.

##### *Indeterminate Nodules (excluding suspicious for malignancy):*

Indeterminate nodules, namely, follicular lesion and neoplasm cannot be further distinguished benign from malignant on cytopathology. These nodules are usually recommended for surgical removal by lobectomy for definitive diagnosis. Given the higher risk of malignancy, follicular neoplasms are more often sent to surgery than follicular lesions. Repeat advances in molecular testing can help identify these lesions as benign or malignant.

#### Molecular Testing

Indeterminate lesions classically went to surgery for diagnostic purposes. While surgery is still the gold standard, recent advances in molecular testing have been able to further categorize these lesions to aid in treatment planning.

Consideration of the use of molecular markers such as BRAF, RAS, RET/PTC, PAX8-PPAR $\gamma$  are suggested by some guidelines. The detection of these markers in a thyroid nodule has shown a sensitivity of 60-86%, but a specificity of 97-100%. This would suggest that if present, the risk of malignancy is high, Nonetheless, malignancy may still be present in the absence of these markers. The testing of these molecular markers can be helpful in preoperative planning.

A more recent addition to the panel of molecular testing (shared in abstract form, not yet published) offers a negative predictive value of 96% for malignancy. This data would suggest that this panel is excellent at predicting the "benignity" of these indeterminate lesions. This test potentially can prevent unnecessary surgeries in thyroid nodule patients. This Veracyte $\text{\textcircled{C}}$  molecular panel test is now CLIA certified and an increasing number of centers are incorporating this testing in the diagnostic workup of their thyroid nodules.

Continued on Page 3

## Upcoming Events

**American Society for Bone and Mineral Research (ASBMR) 2011 Annual Meeting** Sept 16-20, 2011. San Deigo, CA. (<http://www.asbmr.org/Meetings/AnnualMeeting.aspx>)

**ThyCa Conference 2011.** Oct 14-16, 2011. Los Angeles, CA. (<http://www.thyca.org/conferences/html>)

**4th Current Concepts in the Management of Thyroid and Parathyroid Neoplasms.** Oct 20-23, 2011. Sante Fe, New Mexico. (<http://www.mdanderson.org/education-and-research/education-and-training/schools-and-programs/cme-conference-management/conferences/index.html>)

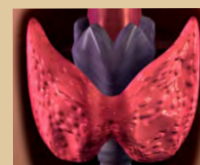
**American Thyroid Association ATA's 81st Annual Meeting** October 26-30, 2011. Indian Wells, CA. ([http://www.thyroid.org/ann\\_mtg/2010\\_81st/index.html](http://www.thyroid.org/ann_mtg/2010_81st/index.html))

**Clinical Diabetes & Endocrinology in 2012** Conference January 21-25, 2012. Aspen, Co. ([www.intellyst.com/diabetesconference](http://www.intellyst.com/diabetesconference))

**15th International Congress of Endocrinology.** May 5-9, 2012. Florence, Italy. ([www.endosociety.com](http://www.endosociety.com))

**American Society of Clinical Oncologists (ASCO) 2011 Annual Meeting** June 1-5, 2012. Chicago, IL. (<http://chicago2012.asco.org>)

**ENDO: The Endocrine Society Annual Meeting 2012.** June 23-26, 2012. Houston Texas. ([www.endo-society.org](http://www.endo-society.org))



(Busaidy, continued from page 2)

### Special circumstances

#### Children:

Thyroid nodules in children should be evaluated by pediatricians/endocrinologists and ultrasonographers versed in a child's neck. The diagnostic evaluation of a thyroid nodule in a child should be the same as in the adult. For further therapeutic decisions, one must seek out a pediatric endocrinologist or a specialist versed in the treatment of pediatric thyroid nodules.

#### Pregnant women:

Pregnant women can safely have an FNA during pregnancy, unless their TSH is suppressed. For women with a suppressed TSH that persists after first trimester, FNA can be deferred until after pregnancy and lactation so a radionuclide scan can be safely performed to evaluate the function of the nodule. Surgery for suspicious nodules and cancerous nodules can wait until after 24 weeks of pregnancy or in some cases after pregnancy.

#### Chronic Diseases/Cancer:

Some patients may have other acute medical issues ongoing

at the time a thyroid nodule is discovered. Some such patients include those with metastatic carcinoma of non-thyroid origin or a chronic disabling disease. In these circumstances a careful well-thought out discussion with the patient should take place prior to the decision for FNA or surgery.

### Summary

Thyroid nodule patients should be evaluated by a multidisciplinary team (physicians, endocrinologists, surgeons, cytopathologists and radiologists) with expertise in thyroid nodules. In order to decrease anxiety and hasten diagnostic and therapeutic planning, patients should be given their results on the same day, as is done in the Thyroid Nodule Clinic in the Endocrine Center at our institution.

### Selected References:

1. Revised American Thyroid Association management guidelines for patients with thyroid nodule and differentiated thyroid cancer. *Thyroid* 19, 1167-1214 (2009).
2. NCCN guidelines accessed on 7-25-2011 at: [http://www.nccn.org/professionals/physician\\_gls/pdf/thyroid.pdf](http://www.nccn.org/professionals/physician_gls/pdf/thyroid.pdf)
3. Baloch ZW, Cibas ES, Clark DP, Layfield LJ, Ljung B, Pitman MB, Abati A. The National Cancer Institute Thyroid fine needle aspiration state of the science conference : A summation. *CytoJournal* 2008;5:6

## MD Anderson Ranks Along Houston's Best Hospitals

MD Anderson Cancer Center was again ranked as No. 1 in cancer care in U.S. News & World Report's list of the Best Hospitals in the nation. Its Diabetes and Endocrinology specialty has been ranked as the best in Houston and the 28th in the country.

The data was based on the U.S. News & World Report's 2011-2012 Best Hospitals Survey. U.S. News states that the new metro rankings are aimed at consumers who may not require the special expertise found only at a nationally-ranked hospital. To be ranked, a hospital had to score in the top 25% among medical institutions and hospitals, and have at least one of 16 medical specialties

## Thyroid Nodule Clinic



The Thyroid Nodule Clinic serves as a resource for our physicians and all patients with thyroid nodules. We aim to provide an exceptional experience for the community physician and their adult and pediatric patients.

Getting a rapid and accurate diagnosis in one place at one time for a patient anxious about whether or not they might have cancer, improves the experience for all those involved. The experienced multidisciplinary team of endocrinologists, surgeons, mid-levels, cytopathologists radiologists and ultrasonographers at MD Anderson are here to help you. We also have two pediatric endocrinologists who can evaluate pediatric patients of all ages.

All patients receive within one day:

- Consultation with a thyroid specialist
- Thyroid ultrasound
- Thyroid biopsy, if needed
- Multidisciplinary conference to discuss treatment options, if needed.

The Thyroid Nodule Clinic is located inside the Endocrine Center at MD Anderson Cancer Center at 1515 Holcombe in Houston, Texas.

For more information or to refer a patient for an appointment:

New Patient Referral Coordinators: 713-563-4400, and 713-792-5410 for patients under 18 years of age.

Physician to Physician Referrals: 713-792-2841

Online Referrals: <https://my.mdanderson.org/>

**ENDOPERSPECTIVES**® is a publication of the Department of Endocrine Neoplasia and Hormonal Disorders at The University of Texas MD Anderson Cancer Center.

### Chair

Steven I. Sherman, M.D.

### Department Administrator

Carol Atwood, M.A., F.A.C.H.E.

### Editor

Charles Stava, M.S.H.A.

### Newsletter Committee Members

Carol Atwood, M.A., F.A.C.H.E.

Mimi I. Hu, M.D.

Lorraine Medina

Lea S. Tatar, M.Ed.

Steven G. Waguespack, M.D.

If interested, please send submissions to Charles Stava, [cstava@mdanderson.org](mailto:cstava@mdanderson.org). We reserve the right to edit for length, content, and style.

Website: <http://www.mdanderson.org/education-and-research/departments-programs-and-labs/departments-and-divisions/endocrine-neoplasia-and-hormonal-disorders/index.html>



# The Combined Role of Ultrasound and Ultrasound Guided Fine-Needle Aspiration of Thyroid Nodules: The MDACC Experience

**Michael Kwon, MD; Matthew Debnam, MD; Brett Monroe, MD; Maria K. Gule, MD; Salmaan Ahmed, MD; Think Vu, MD; Komal Shah, MD; Louis B. Fornage, EMT; David Schellingerhout, MD; Beth S. Edeiken, MD**

Ultrasound (US) and US-guided fine needle aspiration (FNA) have become the methods of choice for early diagnosis of thyroid cancer. This is due in part to the limitations of computed tomography (CT) and positron emission tomography/computed tomography (PET/CT) that may not reveal subcentimeter nodules. There are limitations to physical examination as well. Approximately 50% of the nodules measuring 1–2 cm in maximum diameter, and 94% of thyroid nodules less than 1 cm in size, are not palpable but are visible on US.

US evaluation for thyroid cancer at The University of Texas MD Anderson Cancer Center (MDACC) includes imaging of the thyroid as well as the lymph nodes in the bilateral jugular territories. Inclusion of the bilateral lymph nodes is based on the pattern of metastasis which occurs to the ipsilateral and/or contra lateral nodes in the anterior and posterior jugular territories. In thyroid cancer patients who have a comprehensive evaluation of the soft tissues of the neck at MDACC, US detects disease in neck compartments believed to be negative by PE, CT, and PET/CT in 39% of patients.

The focus of this article is the discussion of the MDACC experience in US imaging and US-guided FNA of thyroid nodules.

## **US Technology:**

Ultrasound of the soft tissues of the neck is performed with high resolution scanners with Color and power Doppler capability. The images are produced with small parts high-frequency (from 7 up to 17-MHz) linear-array transducers.

## **US Examination:**

US examination is performed and interpreted by radiologists, clinicians and surgeons who develop expertise in US imaging and US-guided biopsy. At MDACC, these examinations are performed in the Neurointerventional Radiology (NIR) Clinic by technologists specifically trained and experienced in imaging diseases of the head and neck. Interpretation of the images, and US-guided FNA, are performed by neuroradiologists, who correlate the US findings with those from other imaging modalities, such as CT, MRI, and PET/CT examinations.

## **US Features of Thyroid Nodules:**

US features of a benign thyroid nodule include a simple or complex cyst with no intranodular calcification or vascular flow on power Doppler imaging (PDUS). Intranodular punctate regions of echogenicity with “comet tail” artifacts are also suggestive of a benign thyroid lesion. These punctate echoes represent crystalline colloid and must be differentiated from calcifications with acoustic shadowing. (Fig 1: a, b.)

The diagnosis of a malignant thyroid nodule relies on the combination of US features and results of US-guided FNA, which is often needed because of the overlap in US grayscale features of benign and malignant solid and complex lesions. Approximately 10,000 US examinations of the soft tissues of the neck and 3,000 FNAs are performed annually at the NIR clinic. Based on this experience, US features that have been found to be valid criteria to raise the concern for malignancy of a thyroid nodule include: intranodular calcifications (regardless of pattern or number); intranodular vascularity documented by PDUS (independent of pattern or amount);

presence of a complex nodule with vascularity within the solid component on PDUS; presence of a solitary solid thyroid nodule even in the absence of intranodular calcification and /or intranodular vascularity (Fig 2: a,b) presence in a multinodular thyroid of a non-dominant nodule with malignant characteristics, e.g., intranodular calcification or vascularity (Fig 3).

In our experience, the size and shape (taller than wide) of a nodule are not powerful indicators of malignancy. It was initially reported in the literature that small nonpalpable thyroid nodules incidentally discovered on MR, CT, or US performed for nonthyroid indications were more likely to be benign. However, the documentation of the potential biological aggressiveness of subcentimeter thyroid nodules as small as 0.2 cm, and the higher incidence of associated regional nodal metastasis, indicate that such nodules should be approached with the same concern for malignancy as larger nodules. US detection of subcentimeter nodules is particularly critical because most are nonpalpable and not seen on other imaging modalities. In that context, standard of care must now include the ability to perform an US-guided FNA of such minute lesions.

Although not a contributor to the determination if a thyroid nodule is more or less suspicious for malignancy, the location of the nodule may impact on the therapeutic decision for earlier intervention. Malignant thyroid nodules adjacent to the trachea, esophagus, carotid artery, jugular vein and muscles may invade the anatomic structure as they grow. These nodules should be assessed based on location independent of size (Fig 4).

## **US-Guided FNA of Thyroid Nodules:**

US-guided FNA has become the cornerstone in the confirmation (or exclusion) of thyroid cancer. At MDACC, US-guided FNA of the thyroid is performed with the freehand guidance technique. Following preparation of the skin with rubbing alcohol, approximately 2 cc of Xylocaine are injected via a 25-gauge needle along the planned pathway of the FNA needle all the way to the edge of the targeted nodule. Then a 20-gauge needle attached to a 20-cc syringe is inserted under ultrasound guidance, in alignment with the transducer’s scan plane, so that the echogenic needle can be seen in real time during the entire procedure, which guarantees safety and accuracy. When the tip of the needle has reached the target, aspiration is performed.

The high success rate of US-guided FNA at MDACC is related to the use of a relatively large (20-gauge) needle and constant real-time visualization of the needle tip within the targeted nodule. The 20-gauge 1.5-inch hypodermic needle is stiffer than the 25-gauge or 27-gauge needles used by many practitioners. The stiffer needle allows accurate guidance into calcified, deep, fibrotic, small or mobile thyroid nodules and through scars and adhesions in the post-operative neck. Complications such as bleeding, infection and pain are rarely encountered. The 20-gauge needle has the added benefit of yielding abundant material for cytologic review often with a single FNA pass. In 97% of the patients a single biopsy pass yields sufficient aspirate for a 98% accurate diagnosis.

Continued on Page 5

(Edeiken, continued from page 5)

At the NIR Clinic at MDACC, core-biopsy of the thyroid is restricted to suspected cases of anaplastic tumors and to lymphoma.

**Conclusion:**

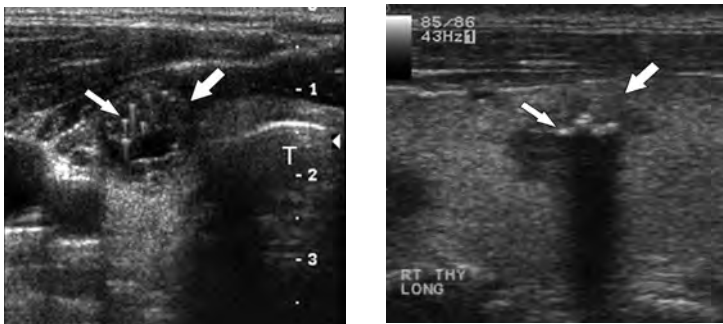
US is sensitive but not specific in the evaluation of thyroid nodules due to the overlap of benign and malignant US features. The most important features that raise the concern for malignancy in a thyroid nodule are intranodular calcification, intranodular vascularity and the presence of a solitary lesion. US-guided FNA is the standard to confirm or rule out malignancy.

A bond of trust, dependent upon highly skilled, experienced, and intellectually committed sonographers, must be established with the surgeons and physicians so that the US information can serve as an accurate pretreatment assessment and can be relied

upon to define and document the location and extent of thyroid cancer.

Ultimately, ultrasound is a combination of science and art. The success of the NIR Clinic at MDACC is based on the ongoing teamwork of the faculty, technologists, APNs and support staff. Thus, the authors would like to thank the technologists Rosie Liboiron (supervisor), Tiffany Isom, Amanda Burrows, Neha Pandya, Ancy George, Jeremy Bass, Ibi Opuiyo and Christy Rodriguez; the APNs Olivia Hua and Li-Ling Hwang; the Radiology Assistants Ghia Jimenez, April Walker, and Maryin Pena; the coordinators Kim Newton and Junaika Davis; Elizabeth Ninan, PA; and the Clinic Manager Tonya Brightmon, MBA, for their continued dedication to the diagnosis and care of our patients. Our patients benefit mightily from their knowledge and teamwork.

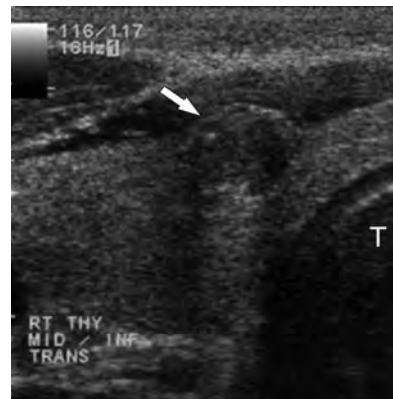
**Fig 1: Comparison of benign crystalline colloid Vs calcification in thyroid nodules**



a. Ultrasound image, in the transverse plane, showing a 1 cm right thyroid mass (larger arrow) with echogenic foci having a comet tail appearance (smaller arrow) caused by crystalline colloid indicative of a benign colloid nodule.

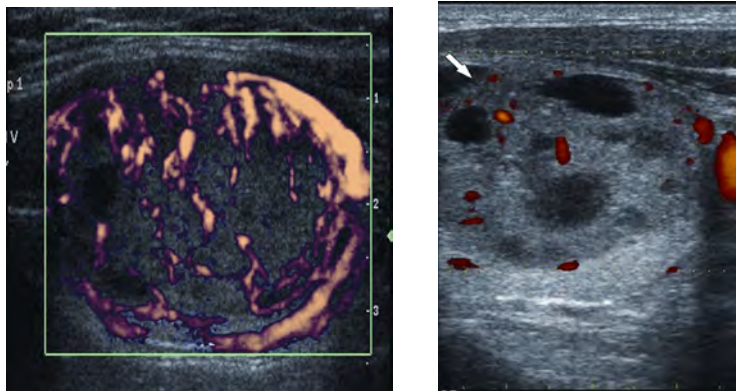
b. Ultrasound image, in the longitudinal plane, of a 1 cm mass (larger nodule) containing echogenic foci that are calcifications with shadowing of concern for a malignant nodule. Subsequent US-guided FNA confirmed a papillary carcinoma.

**Fig 3: Demonstration that it is not always the largest nodule that is malignant.**



Ultrasound image, in the transverse plane, of a 2.3 cm complex nodule biopsied performed with seven passes at an outlying hospital. The slides were interpreted at MDACC as non-diagnostic cytology and a re-biopsy was requested. FNA of the larger nodule (larger arrow) was interpreted as adenoma and FNA of the smaller adjacent nodule was a papillary carcinoma.

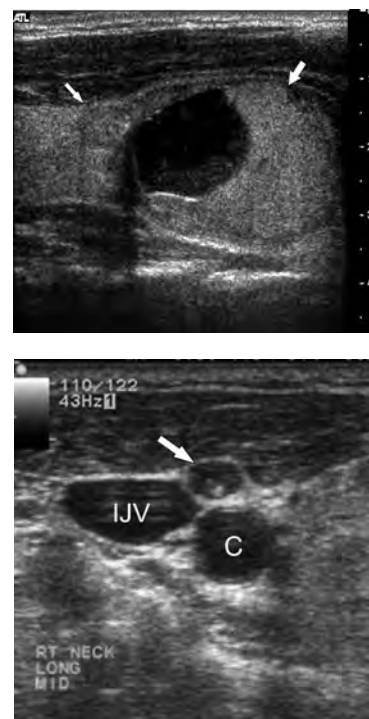
**Fig 2: Solitary nodules in the right thyroid of two different patients demonstrating the overlap in characteristics of benign and malignant lesions.**



a. Ultrasound image, in the transverse plane, of a 2.2 cm solitary solid vascular right thyroid nodule of concern for a malignant thyroid nodule. US-guided FNA confirmed a colloid nodule demonstrating the overlap of ultrasound features of benign and malignant thyroid nodules.

b. Ultrasound image, in the transverse plane, of a 2 cm solitary complex right thyroid mass (arrow) with scant vascular flow suggestive of a colloid nodule. US-guided FNA confirmed a papillary carcinoma again demonstrating the overlap in features of a benign and malignant thyroid mass.

**Fig 4: Demonstration of the important of location of a thyroid mass independent of size.**



Ultrasound image, in the transverse plane, of a subcentimeter right thyroid mass (arrow) that was not biopsied due to size. In six month ultrasound follow-up biopsy revealed tall cell papillary carcinoma that at surgery was found to have invaded the trachea.

## Robotic Surgery for the Thyroid



**Chris Holsinger, MD, FACS**  
**Associate Professor**  
**Department of Head and Neck Surgery**

As thyroid disease evolves, surgeons must adapt to keep pace. But since 1909, when Theodor Kocher, MD became the first surgeon to win the Nobel Prize in Medicine for his work in standardizing the surgical technique for thyroid surgery, little has changed. Minimally invasive video-assisted thyroidectomy became popular ten years ago and permitted surgeons to reduce

the size of the neck incision, but the approach to the thyroid and parathyroid glands essentially remained the same.

Robotic surgery has ushered in a new era of endoscopic head and neck endocrine surgery, providing surgeons with unprecedented visualization of the thyroid, parathyroids and even the lateral neck. In Seoul, South Korea, a team of surgeons led by Professor Woong Youn Chung, MD, of Yonsei University College of Medicine, have described a new way to perform thyroidectomy without leaving a scar in the neck.

Using the da Vinci robotic surgical system (Intuitive Surgical, Sunnyvale, CA), the thyroid gland can be safely removed through incisions in the folds and creases of the upper arm or even in the hairlines behind the ear. Surgeons here at the University of Texas M.D. Anderson Cancer Center in Houston have led the way to study, implement and refine robotic thyroidectomy in the United States.

A 1-2 inch incision in the folds of the axilla is used to establish a working space and create access to the neck and paratracheal bed. Robotic arms, which have been customized to resemble standard surgical instruments, such as the Harmonic Scalpel and the dissecting soft-tissue forceps, can then be used to remove tumors of the thyroid and selected parathyroid disease. These instruments can move with seven degrees of movement and rotate 540 degrees, giving the surgeon the ability to manipulate delicate tissues with precision through remote access, avoiding a neck scar. Sitting at a console just a few feet from the patient, the surgeon then performs the surgery controlling these robotic instruments as he would his own hands, while viewing the patient's anatomy on a 3-D high-definition screen, magnified up to 10 times the normal view. Further, with three robotic arms, the da Vinci robotic system allows the surgeon to operate endoscopically as would be possible in a typical open surgical environment. One instrument can grasp tissue, another provides counter-traction, while a third instrument (usually the Harmonic scalpel) can divide or manipulate the intervening tissue.

Robotic thyroid surgery evolved from endoscopic techniques developed more than a decade ago in Asia. Using standard laparoscopic equipment and carbon dioxide insufflation, the thyroid and parathyroid glands could be approached through small, remote "ports" in the axilla, neck, or breast. However, these procedures were technically difficult and, as such, were not widely accepted. Straight-stick laparoscopic instruments limited dexterity. Monocular vision limited visualization. Chung and his team in Seoul eliminated many of these shortcomings by using the da Vinci Surgical system, which was approved by the Food and Drug

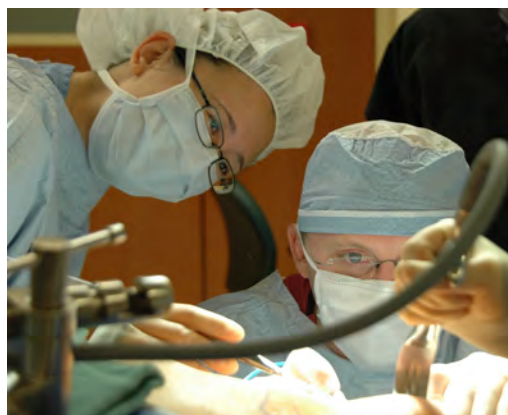Administration (FDA) for human use in 2000.

Which patients then are ideally suited for robotic surgery of the thyroid? Patients with likely benign tumors, usually follicular lesions, measuring 3-centimeters or less, requiring unilateral thyroid lobectomy, are optimal candidates for robotic thyroidectomy. Contraindications include tumors greater than 5 cm in size, retropharyngeal goiter and/or lesions located at the posterior capsule in the tracheoesophageal groove. Patients with known malignancy and especially those with paratracheal metastasis are not ideal for robotic surgery at this time. Finally, body habitus and BMI may also be important considerations, as well.

Optimal Candidates for Robotic Surgery
Likely benign tumors $\leq$ 3cm in size
Pathology requiring unilateral lobectomy
Body Mass Index of less than 40

Postoperative management is similar to open minimally invasive thyroid surgery. A drain can be used and placed through the axilla incision and usually can be removed on postoperative day 1 or 2. Early in our experience, patients have been kept overnight and discharged from the hospital the morning following surgery. Because of larger working space, the risk of postoperative airway compression from hematoma is lower than with conventional open surgery, and it may also soon be reasonable to discharge patients on the same day of surgery.

While robotic thyroid surgery may provide new advantages, it is not without its shortcomings. The robotic procedure may be more time-consuming. While remote access from the axilla eliminates a neck scar, it is more difficult to approach the contralateral recurrent laryngeal nerve. As such, its early use in the United States has been limited to lobectomy. Prospective clinical trials in Korea demonstrate the superiority of robotic, over standard laparoscopic, thyroid surgery, but data comparing robotic to standard open thyroid surgery are just now emerging.

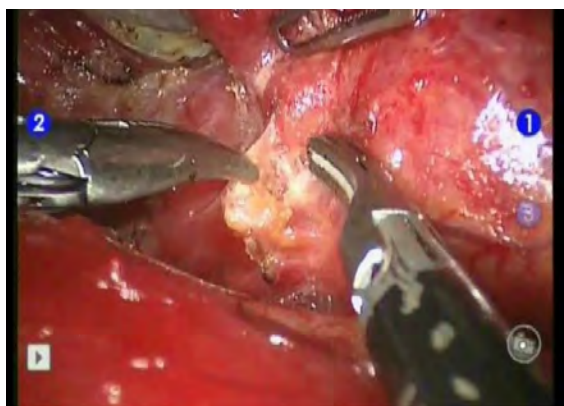

**Dr Holsinger (on right) establishing the working space for robotic thyroidectomy.**



Chris Holsinger, MD, FACS, Associate Professor of Head and Neck Surgery, at the University of Texas MD Anderson Cancer Center, published the first experience with Chung's robotic thyroid technique in North American in January 2010.<sup>1</sup> Other centers around the United States and throughout Europe have since adopted and published on this technique, demonstrating its reproducibility for unilateral lobectomy.

What is its role for total thyroidectomy? While robotic surgery for total thyroidectomy in Korea is commonly performed<sup>2-4</sup>, Lee et al. have recently highlighted the importance of experience and the potentially steep learning curve<sup>5</sup> for robotic thyroid surgery. Robotic surgery requires not merely a skilled and experienced surgeon, but also a great operating room team, as Perrier et al. have recently described, for the implementation of this novel technique.<sup>6</sup> Robotic thyroidectomy may introduce new perioperative risks, not typically associated with thyroid surgery and so further prospective and multicenter study is clearly indicated.



Robotic instrumentation identifying the right superior parathyroid gland during thyroid surgery.

Should robotic thyroid surgery be used routinely for cancer?

Right now, in the United States, the answer is no. The oncologic efficacy of robotic thyroid surgery has not yet been established and is only just now being studied. Lee et al. examined serum thyroglobulin levels after radioactive iodine and found no difference in patients undergoing robotic or laparoscopic thyroid surgery. But Tae et al. compared patients undergoing robotic surgery with patients having open thyroidectomy and did find significantly higher rates of TSH-stimulated serum thyroglobulin before RAI in patients undergoing robotic surgery—though these normalized after remnant ablation.

So clearly, further study is required. A framework for surgical investigation should begin first by examining rigorously the US multicenter experience, and thereby to establish the safety and efficacy of robotic surgery for lobectomy. Then, further prospective comparative trials can proceed, if this technique is right for patients.

Holsinger concludes, "Robotic thyroid surgery is not only about avoiding a scar; it's about better surgery. I think robotic thyroidectomy has the potential to change the way head and neck surgery is done across the board. In the next five years, with robotics as a common platform, I suspect that we'll see a variety of innovative procedures for the thyroid and neck, from lobectomy to comprehensive neck dissection."<sup>7</sup>

#### References

1. Lewis CM, Chung WY, Holsinger FC. Feasibility and surgical approach of transaxillary robotic thyroidectomy without CO(2) insufflation. *Head Neck* 2010;32(1): 121-6.
2. Tae K, Ji YB, Jeong JH, Lee SH, Jeong MA, Park CW. Robotic thyroidectomy by a gasless unilateral axillo-breast or axillary approach: our early experiences. *Surg Endosc* 2011;25(1): 221-8.
3. Lee S, Ryu HR, Park JH, et al. Excellence in robotic thyroid surgery: a comparative study of robot-assisted versus conventional endoscopic thyroidectomy in papillary thyroid microcarcinoma patients. *Ann Surg* 2011;253(6): 1060-6.
4. Lee J, Kang SW, Jung JJ, et al. Multicenter Study of Robotic Thyroidectomy: Short-Term Postoperative Outcomes and Surgeon Ergonomic Considerations. *Ann Surg Oncol* 2011.
5. Lee J, Yun JH, Nam KH, Soh EY, Chung WY. The learning curve for robotic thyroidectomy: a multicenter study. *Ann Surg Oncol* 2011;18(1): 226-32.
6. Perrier ND, Randolph GW, Inabnet WB, Marple BF, VanHeerden J, Koppersmith RB. Robotic thyroidectomy: a framework for new technology assessment and safe implementation. *Thyroid* 2010;20(12): 1327-32.
7. Holsinger FC, Sweeney AD, Jantharapattana K, et al. The emergence of endoscopic head and neck surgery. *Curr Oncol Rep* 2010;12(3): 216-22.

## Recent News from the Endocrine Team

- Congratulations to Drs Victor Lavis, Steven Sherman, Steven Waguespack, Mimi Hu, Rena Vassilopoulou-Sellin, and Anita Ying for making the list of US News & Report Top Doctors. US News Top Doctors was created in collaboration with Castle Connolly Medical LTD, publisher of *America's Top Doctors*®, and based on data gleaned from *Castle Connolly's Top Doctors*™. They were chosen for their ability to address their patients' needs and considered by other doctors as amongst the most recommended for referral.

- Dr Naifa Busaidy received a grant from the American Thyroid Association (ATA) to investigate the role of the PI3 kinase pathway in progression of thyroid cancer and also the prognostic role of the PI3 kinase pathway in braf mutant papillary thyroid carcinomas

#### Publications:

- Drucker DJ, Sherman SI, Bergenstal RM, Buse JB. The safety of incretin-based therapies, review of the scientific evidence. *J Clin Endocrinol Metab*. 2011 Jul;96(7):2027-31.

- Kurzrock R, Sherman SI, Ball DW, Forastiere AA, Cohen RB, Mehra R, Pfister DG, Cohen EE, Janisch L, Nauling F, Hong DS, Ng CS, Ye L, Gagel RF, Frye J, Muller T, Ratain MJ, Salgia R. Activity of XL184 (Cabozantinib), an Oral Tyrosine Kinase Inhibitor, in Patients With Medullary Thyroid Cancer. *J Clin Oncol*. 2011 Jul 1, 29(19):2660-6. Epub 2011 May 23.

- Stephen MD, Zage PE, Waguespack SG. Gonadotropin-dependent precocious puberty: neoplastic causes and endocrine considerations. *Int J Pediatr Endocrinol*. 2011, 2011:184502. Epub 2011 Mar 6.

- Khan MI, Habra MA, McCutcheon IE, Noguerras-Gonzalez GM, Devin JK, Busaidy NL, Levin NB, Lindstrom W, Kagan D, Jimenez C, Waguespack SG. Random postoperative day 3 cortisol as a predictor of hypothalamic-pituitary-adrenal axis integrity after transsphenoidal surgery. *Endocr Pract*. 2011 Mar 31:1-25.

- Khan MI, Waguespack SG, Habra MA, Broaddus R, Jimenez C. Acute-onset ectopic adrenocorticotrophic hormone syndrome secondary to metastatic endometroid carcinoma of the ovaries as a fatal complication. *J Clin Oncol* 2011 Jun 1;29(16):3462-4.

- Ejaz S, Vassilopoulou-Sellin R, Busaidy NL, Hu MI, Waguespack SG, Jimenez C, Ying AK, Cabanillas M, Abbara M, Habra MA. Cushing syndrome secondary to ectopic adrenocorticotrophic hormone secretion: The University of MD Anderson Cancer Center experience. *Cancer*. 2011 Mar 15 doi: 10.1002/cncr.26029 (Epub ahead of print).

- Hu, MI. Updates in the management of medullary thyroid cancer. *Clin Adv Hematol Oncol*. 2011 May;9(5):391-4.

- Yeung SC, Habra MA, Thosani SN. Lung cancer-induced paraneoplastic syndromes. *Curr Opin Pulm Med*. 2011 Jul;17(4):260-8.

- Cabanillas ME, Kantarjian H, Thomas DA, Mattiuzzi GN, Rytting ME, Bruera E, Xia L, Bekele BN, Foudray MC, Cortes JE. Epoetin alpha decreases the number of erythrocyte transfusions in patients with acute lymphoblastic leukemia, lymphoblastic lymphoma, and Burkitt leukemia/lymphoma: Results of a Randomized Clinical Trial. *Cancer*. 2011 Jul 12. doi: 10.1002/cncr.26341 (Epub ahead of print).

## Wish to make a donation to Endocrine Research?

You can make a huge difference in the lives of those with endocrine tumors and hormonal disorders by donating to our endocrine research fund. New discoveries pertaining to endocrine malignancies can also combat other types of cancers. We now have a webpage for your convenience: <http://www.mdanderson.org/education-and-research/departments-programs-and-labs/departments-and-divisions/endocrine-neoplasia-and-hormonal-disorders/endocrine-research.html>

## How to refer a patient to MD Anderson



### Online Referrals:

MD Anderson has created an online referral process, myMDAnderson, to help you get your patient into MD Anderson as quickly as possible. You can use myMDAnderson to follow your patient's treatment regimen by viewing transcribed reports and accessing your patient's schedules. To qualify for this free service, you must be a licensed, practicing physician. To start a referral through myMDAnderson, please access this portal:

<https://my.mdanderson.org/public/physicians/user/>

### Telephone Referrals:

- Physician to Physician referrals, please call 713-792-2841.
- To speak with a New Patient Referral Coordinator, please call 713-563-4400.
- For Pediatric Referrals (patients less than 18 years of age), please call 713-792-5410.

## Department of Endocrine Neoplasia and Hormonal Disorders Faculty

Steven I. Sherman, M.D., Chair and Professor  
and Center Medical Director, Endocrine Center  
Naifa L. Busaidy, M.D., Assistant Professor  
Rozita Bagheri-Yarmand, Ph.D., Assistant Professor  
Maria E. Cabanillas, M.D., Assistant Professor  
Gilbert J. Cote, Ph.D., Professor  
Robert F. Gagel, M.D., Professor  
Mouhammed A. Habra, M.D., Assistant Professor

Mimi I. Hu, M.D., Assistant Professor  
Camilo Jimenez, M.D., Assistant Professor  
Victor R. Lavis, M.D., Professor  
Sara Peleg, Ph.D., Associate Professor  
Rena Vassilopoulou-Sellin, M.D., Clinical Professor  
Steven G. Waguespack, M.D., Associate Professor  
Sai Ching Jim Yeung, M.D., Ph.D., Associate Professor  
Anita K. Ying, M.D., Assistant Professor