



Multiple Endocrine Neoplasia Type 2: A Case-Based Discussion

THE UNIVERSITY OF TEXAS
**MD Anderson
Cancer Center**
Department of Endocrine Neoplasia
and Hormonal Disorders

Making Cancer History[®]



Mimi I. Hu, MD
Assistant Professor
Department of Endocrine Neoplasia and Hormonal Disorders

A 20 year-old woman presents for initial evaluation due to her concern regarding a family history of medullary thyroid cancer and pheochromocytoma. She noted a mass on her right lower neck about a year ago but denies having any diarrhea,

flushing or compressive symptoms. She denies having kidney stones, abdominal pain, elevated blood pressures, palpitations or nervousness.

Hereditary medullary thyroid carcinoma (MTC) presents within the context of 3 genetic syndromes. Multiple endocrine neoplasia type 2A (MEN2A, Sipple's syndrome) is an autosomal-dominant genetic syndrome that includes MTC, pheochromocytoma, and primary hyperparathyroidism (PHPT). MEN2B is an autosomal-dominant genetic syndrome that includes MTC, pheochromocytoma, multiple mucosal neuromas, and a marfanoid habitus. Familial medullary thyroid carcinoma (FMTC) refers to a variant of MEN2A in which MTC is the only clinical manifestation. These hereditary syndromes are uncommon; probably fewer than 1500 kindreds are recognized worldwide. MEN2 is estimated to affect 1 out of every 30,000-50,000 people. MEN2A is more common than FMTC, while MEN2B is the least common hereditary syndrome of the three.

MEN2 and FMTC are caused by germline mutations in the RET proto-oncogene located on chromosome 10 that lead to the expression of a constitutively, active RET transmembrane tyrosine kinase receptor. In addition, somatic RET proto-oncogene mutations have been found in approximately 25% of patients with sporadic MTC. The RET receptor is characterized by a large extracellular portion that interacts with ligands and co-receptors. The extracellular portion of the receptor also contains regions necessary for the tertiary structure of the protein and for recep-

tor dimerization. The intracellular domain of the RET receptor contains two tyrosine kinase regions that activate intracellular signal transduction pathways. RET activation leads to the autophosphorylation of tyrosine residues on the intracellular domains of RET. The activated tyrosine residues serve as docking sites for adaptor proteins, which coordinate cellular signal transduction pathways (e.g., MAPK, PI3K, AKT, JNK, ERK) and are important in the regulation of cell growth (1). The RET receptor is expressed by neural crest-derived cells: thyroid C-cells, adrenal medullary cells, parasympathetic/sympathetic/colonic ganglia, urogenital tract cells, and parathyroid cells.

MEN2A is characterized by MTC in more than 90% of gene carriers, unilateral or bilateral pheochromocytomas in 50% of gene carriers, and parathyroid hyperplasia approximately 20% of carriers. Unlike what is seen with MEN type 1, the hyperparathyroidism seen in MEN2A rarely occurs early in life, with the reported median age of diagnosis of 38 years (2). Other rare variants of MEN2A exist. MEN2A with Hirschsprung's disease is an uncommon variant where children present in childhood with megacolon or obstructive symptoms. MEN2A with cutaneous lichen amyloidosis has been reported where patients exhibit a pruritic, cutaneous form of amyloid located over the upper back (3).

(Continued on page 2)

Table of Contents

Multiple Endocrine Neoplasia Type 2: A Case Based Discussion	Page 1
Upcoming Events	Page 2
Notes from the Endocrine Faculty Team	Page 5
Incorporating MEN 1 Genetic Testing as a Diagnostic Tool in Clinical Practice	Page 6
Introducing the new Multiple Endocrine Neoplasia Specialty Clinic at M. D. Anderson Cancer Center	Page 7
Seeking Patients for a Phase II Study	Page 8

(Hu, continued from Page 1)

Most commonly, the skin abnormality develops in the second or third decade of life; however, in some reported examples, localized pruritus was noted during childhood.

MEN2B is less common than MEN2A but is the most distinctive syndrome clinically. MEN2B is characterized by the following: MTC in 100% of carriers; pheochromocytomas in 50% of carriers; mucosal neuromas localized in the distal tongue, lips, eyelids, and the gastrointestinal tract in more than 90% of carriers; and a marfanoid habitus in nearly all affected individuals. C-cell hyperplasia and MTC develop much earlier in MEN2B patients than in those with MEN2A, in general. Early identification of MTC in MEN2B is important because metastases have been described during the first year of life.

MEN2 patients may come to clinical attention when there are symptoms suggestive of underlying MTC: presence of a neck mass, diarrhea (thought to be caused by tumoral production of a humoral factor), flushing, or rarely Cushingoid features (due to ectopic tumoral production of adrenocorticotropic hormone). Pheochromocytomas in MEN2 syndromes are differentiated from the sporadic forms in that they have a relative overproduction of epinephrine, rather than norepinephrine (4). This may account for the observation that patients with hereditary pheochromocytomas exhibit more beta-adrenergic-like symptoms such as tachycardia, palpitations and anxiety-like complaints. Hypertension in these patients is less striking, unless there exists a large pheochromocytoma. Oftentimes, patients may have no symptoms suggestive of an underlying pheochromocytoma, but plasma metanephrines will be elevated. Sudden death related to pheochromocytoma was documented to occur prior to routine prospective screening. Hyperparathyroidism can manifest clinically with development of renal stones, polyuria, constipation or abdominal pain. Finally, patients occasionally will present for initial evaluation due to a family history suggestive of the presence of a MEN syndrome or a RET mutation has been identified in a family member.

The patient undergoes a thyroid ultrasound, which reveals bilateral thyroid masses with central and right cervical lymphadenopathy. Medullary thyroid carcinoma is identified from biopsies of the thyroid mass and right neck lymph node. The patient has blood work performed to evaluate calcium, parathyroid hormone, plasma metanephrines, calcitonin and carcinoembryonic antigen (CEA). She was referred to genetic counseling and consented to have a RET mutational analysis performed.

Genetic testing for MEN2 is extremely valuable for a variety of reasons. The primary goal is

to identify and treat the several manifestations of MEN2 before they become life threatening, which are metastases from MTC and sudden death associated with pheochromocytoma. There are well-established genotype-phenotype correlations in MEN2, such that a specific codon mutation can predict the particular clinical syndrome and course. Of particular note, codon 634 RET mutation is the most common one associated with MEN2A and accounts for almost 80% of mutations in MEN2 (4). Codons 883 and 918 mutations are associated with MEN2B, with 918 being the most common and most aggressive mutation. A risk stratification system was developed by the Seventh International Workshop on MEN based on the aggressiveness of MTC with known RET mutations; this is described in the 2009 American Thyroid Association (ATA) guidelines for MTC management (5). ATA level D mutations (codon 883 and 918) are associated with the highest risk for MTC, developing metastases and youngest age of onset. ATA-C mutations (codon 634) have a lower but high risk for aggressive MTC. ATA-B mutations (codons 609, 611, 618, 620 and 630) impart a lower risk for aggressive MTC. ATA-A mutations convey the "least high" risk (5). An understanding of the risk level is important in counseling patients and family members of timing of prophylactic thyroidectomy, parathyroidectomy and/or screening for pheochromocytoma (See Table 1). A secondary goal with genetic evaluation is to provide information essential in the counseling of family members about the potential for transmission to the next generation.

The decision to have genetic testing is a personal one and should be voluntary. It is important to provide genetic counseling to individuals before obtaining the genetic test to discuss the process of genetic testing, the fundamentals of autosomal-dominant inheritance in MEN2, and clinical features of the syndrome and the implication for family members. The ATA guidelines for MTC recommend that all patients with a personal history of primary C-cell hyperplasia, MTC, or MEN2 or with a family history of MEN2 or FMTC should be offered germline RET testing (5). Licensed genetic counselors can be found via the National Society of Genetic Counselors' website (www.nsgc.org) or the National Institute of Health's Web site (www.cancer.gov/search/genetics_services).

Prior to surgery for clinically apparent MTC, ultrasound of the neck to include the superior mediastinum, central compartment and bilateral lateral neck compartments should be done. Baseline calcitonin, CEA, calcium, and RET analysis should be performed. An underlying pheochromocytoma must be excluded prior to thyroidectomy with one of the following: negative plasma free metanephrines/normetanepfamily history, or negative adrenal CT or MRI (5).

(Continued on Page 3)

Upcoming Events

14th International Thyroid Congress Sept. 11-16, 2010. Paris, France. (www.itc2010.com)

MEN 2010 12th International Workshop on Multiple Endocrine Neoplasia Sept. 16-18, 2010. Gubbio, Italy (www.men2010.com)

North American Neuro-Endocrine Tumor Society Annual Conference October 29-30, 2010. Santa Fe, New Mexico (www.nanets.net)

14th Asia-Oceania Congress of Endocrinology December 2-5, 2010. Kuala Lumpur, Malaysia (www.aoce2010.com)

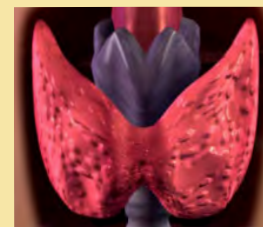
AACE 20th Annual Meeting and Clinical Congress. April 13-17, 2011. San Diego, CA. (www.aace.com)

Endocrine Society's Endo 2011, 93rd Annual Meeting & Expo. June 4-7, 2011. Boston, MA. (www.sherago.com/endocrine/AnnualMeeting.htm)

4th Current Concepts in the Management of Thyroid and Parathyroid Neoplasms. Oct 20-23, 2011. Santa Fe, New Mexico. (website to be announced)

15th International Congress of Endocrinology. May 5-9, 2012. Florence, Italy. (www.endosociety.com)

Pediatric Endocrine Society 2011 Annual Meeting. April 30-May3, 2011. Denver, Colorado. (www.lwpes.org)



(Hu, continued from Page 2)

If an underlying pheochromocytoma is present, it should be surgically resected after appropriate preoperative preparation and prior to surgery for MTC or PHPT. Screening for PHPT prior to a planned thyroidectomy is necessary when MEN2A is suspected or identified, as it is recommended to surgically manage the hyperparathyroidism concomitantly.

The patient had a calcitonin of 300 pg/mL and a CEA of 115 ng/mL. She had normal plasma metanephrines and no evidence of hyperparathyroidism. Her RET analysis revealed a codon 634 mutation. She underwent a total thyroidectomy with central and right lateral compartment neck dissections. Although her calcitonin and CEA declined significantly after her surgery, her levels did not become undetectable.

At present, the only possible curative treatment for MTC is complete surgical resection when the disease is confined to the neck. However, complete resection of MTC could be very difficult. A high percentage of MTC manifesting as a palpable thyroid nodule have metastasized to ipsilateral and contralateral cervical lymph nodes at the time of initial diagnosis and may even have evidence of distant metastatic disease to the liver, bones, and lung parenchyma (1). The recent ATA guidelines recommend that total thyroidectomy with central (level VI) compartment dissection be done with node-negative MTC, while node-positive MTC with undetectable or minimal distant metastases should undergo total thyroidectomy, level VI compartment dissection and lateral neck compartmental dissection for confirmed disease by imaging or biopsy (5). Further surgical recommendations can be reviewed in the ATA guidelines, as complete description is beyond the scope of this article.

Calcitonin and CEA are serum tumor markers used to monitor the progression of MTC. Calcitonin is produced by the C-cells of the thyroid gland and is directly proportional to MTC tumor mass, in most circumstances. Additionally, there is evidence that a rapid rate of progression of calcitonin concentration correlates with increased aggressiveness of MTC and poorer prognosis. A calcitonin doubling time (DT) of less than one year conveys a 10-year survival of 18% compared with 95% 10-year survival for patients with a calcitonin DT of greater than one year (6). The 5-year recurrence free survival is 20% if the calcitonin DT is less than one year, in contrast to 73% if the DT is greater than one year. There are several important points to keep in mind about calcitonin (1). First, calcitonin concentration can be abnormally elevated in the context of pregnancy, oral contraceptive use, goiter, and other tumors (e.g. breast and lung cancer). Second, calcitonin is a secretory peptide whose secretion is episodic and may be affected by plasma calcium concentration, exercise, or gastrin stimulation. Third, de-differentiation of MTC may lead to an

inability to produce calcitonin effectively. Consequently, a decrease in plasma calcitonin in someone with advanced MTC, especially if the CEA is rising, may suggest a poorer prognosis. Finally, after thyroidectomy and lymph node dissection, it can take 2-3 months before the calcitonin and CEA levels reach a nadir due to postoperative inflammatory effects and the prolonged half-life of both.

Although CEA is a useful tumor marker for monitoring MTC progression, it is also produced by the gastrointestinal tract and liver. Its concentration may be elevated in cigarette smokers and persons with other tumor types. Thus, CEA is an insensitive marker for detection of early MTC, but it is a useful long-term indicator of disease progression when elevated. The CEA DT also has prognostic value similar to calcitonin DT (6). The ATA guidelines for MTC have incorporated the estimation or calculation of the doubling time of calcitonin and CEA into their surveillance algorithms (5). A calcitonin and CEA DT calculator can be found on the ATA website (www.thyroid.org).

After thyroidectomy, patients with persistent elevations of calcitonin and CEA are likely associated with residual disease in the cervical lymph nodes. Although distant metastases are possible, the volume is likely small and distant disease may be difficult to localize. In patients with calcitonin concentrations of less than 150 pg/ml, long-term clinical surveillance with periodic ultrasound of the neck is indicated (5). If calcitonin levels are greater than 150 pg/mL, there should be consideration for performing other localization studies to evaluate for distant metastases: neck ultrasound, CT scans of the chest and abdomen with 3-phase contrast enhanced liver protocol, MRI of the spine/pelvis, or bone scan (5). Because the patient has undergone a total thyroidectomy, the decision to perform a neck lymph node dissection should be based on a realistic estimate of the probability of surgical cure. In most circumstances, reoperation of the neck will not normalize serum calcitonin concentrations and the risk of hypoparathyroidism increases (1).

Routine surveillance for development of pheochromocytoma and PHPT in MEN2 patients depends on the RET codon mutation, the predilection toward a particular clinical course, and the patient's known familial pattern of neoplasia development. It is recommended that annual biochemical testing for pheochromocytoma should be performed beginning at 8 years of age in patients with RET mutations associated with MEN2B and in codons 630 and 634, while other MEN2A RET mutations should have testing start at 20 years of age (5). Women of childbearing age with a RET mutation should be screened prior to attempting pregnancy due to the risk to the fetus and mother. Screening radiologic testing for pheochromocytoma is not recommended if a patient is asymptomatic or biochemical testing is negative.

(Continued on Page 4)

ENDOPERSPECTIVES® is a quarterly publication of the Department of Endocrine Neoplasia and Hormonal Disorders at The University of Texas MD Anderson Cancer Center.

Chair

Steven I. Sherman, M.D.

Department Administrator

Carol Atwood, M.A., F.A.C.H.E.

Editor

Charles Stava, M.S.H.A.

Newsletter Committee Members

Carol Atwood, M.A., F.A.C.H.E.
Mimi I. Hu, M.D.
Lorraine Medina
Linda Roden, M.B.A
Lea S. Tatar, M.Ed.
Steven G. Waguespack, M.D.

If interested, please send submissions to Charles Stava, cstava@mdanderson.org. We reserve the right to edit for length, content, and style.

Website: <http://www.mdanderson.org/education-and-research/departments-and-labs/departments-and-divisions/endocrine-neoplasia-and-hormonal-disorders/index.html>

(Hu, continued from page 3)

PHPT surveillance is similar to that for pheochromocytoma with the exception of carriers of MEN2B codon mutations.

Ten years later, the patient's calcitonin and CEA values have slowly progressed with development of bilateral pulmonary, hepatic and vertebral spine lesions without imparting any symptoms of diarrhea, flushing or back pain. The plasma metanephrines were found to be in the high-end of the normal reference range, with the absence of symptoms of pheochromocytoma. The abdominal CT noted a 1 cm right adrenal mass. Laparoscopic adrenalectomy was performed after appropriate preoperative medical therapy, and the pathologic diagnosis was pheochromocytoma. The patient also has not developed hyperparathyroidism.

Preoperative management of patients with pheochromocytoma involves medical therapy with a combination of alpha- and beta-adrenergic blockade for 1-3 weeks prior to surgery and oral hydration to increase intravascular volume. These interventions will minimize the intraoperative complications from tumoral manipulation, which include tachycardia and severe hypertension. Sudden removal of the vasoconstrictive effects of adrenergic hormones with tumor resection can lead to postoperative vascular collapse and hypotension, which can be prevented by adequate fluid hydration preoperatively. Laparoscopic adrenalectomy is the favored approach for removal of a pheochromocytoma (5). In centers with clinical expertise, a posterior retroperitoneal laparoscopic approach is associated with shorter operative times and hospital stays than with open or standard laparoscopic procedures (7).

Biochemical cure of MTC varies depending upon the extent of lymph node involvement at the time of initial surgery, 75%–90% in patients without lymph node involvement and 20%–30% in those with lymph node involvement (8). Distant metastatic disease represents a therapeutic challenge, as there are no curative options available at this time. The available treatments (chemotherapy and external radiation) for unresectable or metastatic MTC are nonspecific for the disease process and have variable outcomes without demonstration of improved long-term survival. Bony metastases can be targeted by intravenous

bisphosphonates, although no data are available to demonstrate a potential benefit of these agents against metastatic MTC bone disease. Symptoms from metastatic disease can be treated selectively, such as with embolization of large hepatic metastases or radiation for skeletal metastases, and aggressive therapy for diarrhea is often necessary. Treatments used for the differentiated forms of thyroid cancer, radioiodine and TSH-suppressive thyroid hormone therapy, are ineffective and not used for MTC.

The identification of activating mutations of the RET proto-oncogene as the cause of almost all cases of hereditary MTC and at least 25% of sporadic MTC and the recent treatment successes with tyrosine kinase inhibitors (TKIs) for other malignancies have driven the investigation of TKIs that also target the RET receptor. Multikinase inhibitors take advantage of the homology between the tyrosine kinase domains of RET, vascular endothelial growth factor receptors (VEGFR), and epidermal growth factor receptor (EGFR). Several compounds (e.g. vandetanib, XL-184, sunitinib, sorafenib) have demonstrated antitumoral activity in MTC, with best response being partial response determined by RECIST criteria (i.e. > 30% reduction of maximal tumoral diameter). To date, cure has not been achieved by any of the TKIs and often initial responses to therapy are not sustainable. Side effects include skin rash, hand-foot syndrome, hypertension, prolonged QTc interval, heart failure, nausea, diarrhea, diminished appetite, and fatigue. However, for patients with progressive, advanced MTC, it is recommended that they be referred for a clinical trial or consider sorafenib therapy, which is FDA-approved for renal cell and hepatocellular carcinoma (5, 9). In addition, to these options, sunitinib is also considered for patients at our institution, especially given recently presented, preliminary results from a large Phase II study (10). It seems possible that one or more of these agents will be approved for the treatment of advanced MTC over the next few years.

The evaluation, management, and long-term surveillance of patients with MEN2 are intriguing and complex. Essential to the care of MEN2 patients is a coordinated multidisciplinary approach involving the patient, family members, and specialists in the fields of endocrinology, oncology, surgery, genetics, radiology, and pathology.

Table 1, ATA Risk Level and Prophylactic Thyroidectomy and Therapy

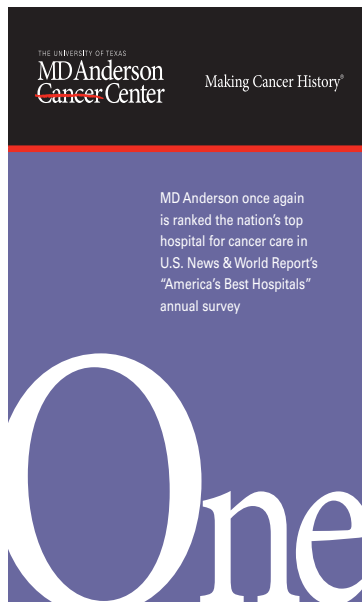
ATA risk level	Age of RET testing	Age of required first US	Age of first serum Ct	Age of prophylactic surgery
D	ASAP and within the 1 st year of life	ASAP and within the 1 st year of life	6 months, if surgery not already done.	ASAP and within the 1 st year of life
C	<3-5 years	>3-5 years	>3-5 years	Before age 5 years
B	<3-5 years	>3-5 years	>3-5 years	Consider surgery before age 5. May delay surgery beyond age 5 years if stringent criteria are met. ^a
A	<3-5 years	>3-5 years	>3-5 years	May delay surgery beyond age 5 years if stringent criteria are met. ^a

^a A normal annual basal ± stimulated* serum Ct, normal annual neck US, less aggressive MTC family history, and family preference. ASAP, as soon as possible.

References:

- Jimenez C, Hu MI, Gagel RF. Management of medullary thyroid carcinoma. *Endocrinol Metab Clin North Am.* 2008, 37(2):481-96.
- Kraimps JL, Denizot A, Carnaille B, et al. Primary hyperparathyroidism in multiple endocrine neoplasia type IIa: retrospective French multicentric study. *World J Surg* 1996, 20:808-12, 1996
- Gagel RF, Levy ML, Donovan DT, et al. Multiple endocrine neoplasia type 2a associated with cutaneous lichen amyloidosis. *Ann Intern Med* 1989, 111: 802-806.
- Hu M, Gagel RF. Multiple Endocrine Neoplasia Type 2. In: *Endocrinology*, 6th edition. Ed(s) LJ DeGroot, JL Jameson. Saunders. 2010
- Kloos RT, Eng C, Evans DB, et al. Medullary thyroid cancer: management guidelines of the American Thyroid Association. *Thyroid* 2009, 19:565-612.
- Meijer JA, le Cessi S, van den Hout WB, et al. Calcitonin and CEA doubling times as prognostic factors in medullary thyroid carcinoma, a structured meta-analysis. *Clin Endocrinol (Oxf)* 2010, 72(4):534-42.
- Walz MK, Alesina PF, Wenger FA, et al. Posterior retroperitoneoscopic adrenalectomy—results of 560 procedure in 520 patients. *Surgery* 2006, 140:943-50.
- Leboulleux S, et al., Medullary thyroid carcinoma. *Clin Endocrinol (Oxf)* 2004, 61(3): p. 299-310.
- Thyroid Carcinoma. NCCN Clinical Practice Guidelines in Oncology, version 2008.
- De Souza JA, Busaidy N, Zimrin A, et al. Phase II trial of sunitinib in medullary thyroid cancer. ASCO Annual Meeting, Abstract #5504, 2010.

Dept. of Endocrine Neoplasia & H.D. Ranked 21st in Nation!



MD Anderson Cancer Center has once again ranked No. 1 in cancer care in U.S. News & World Report's "America's Best Hospitals" annual survey. The institution has achieved the top ranking six of the last nine years, and it has been either first or second in cancer care every year since the survey's inception in 1990.

Several MD Anderson sub-specialties also are ranked among the best in the nation:

- Ear Nose and Throat - No. 6
- Urology - No. 10
- Gynecology - No. 11
- Gastroenterology - No. 19
- Diabetes and Endocrinology - No. 21

Amongst the ranking of pediatric hospitals, our Children's Cancer Hospital was ranked No. 12 in the nation.

"This is a wonderful accomplishment, especially given the jump from #41 last year. Given the narrow focus of our work, and the relatively high morbidity and mortality of the cancer patient population in which we specialize, to be ranked this high is very special. In fact, although we ranked #21 overall, our 8.7% "reputation score" (percentage of endocrinologists in the last 3 years who recommended us) was up to #12 in the nation, reflecting the respect that our peers hold for our work. said Steven I. Sherman, MD., Chair, Dept. of Endocrine Neoplasia and Hormonal Disorders, and Medical Director of the Endocrine Center.

Rankings are based on a reputation survey of board-certified hematologists and oncologists around the nation, nurse-to-patient ratios and Magnet Status, some patient outcomes data, and several advanced technologies and services available to patients and the community.

Notes from the Endocrine Faculty Team

Honor and Recognition:

A round of applause to Steven G. Waguespack, MD, for being appointed as the Deputy Chair of the Department of Endocrine Neoplasia and Hormonal Disorders. He came to M.D. Anderson in 2002 after completing his training in both adult and pediatric endocrinology at Indiana University, and was quickly promoted to Associate Professor in 2007. He has been a highly productive and respected clinician and educator, and has contributed to many of the operational advances in our clinical programs. Holding joint appointment in the Department of Pediatrics, he has also been a valued participant in the Children's Cancer Hospital while rapidly expanding pediatric endocrine services. His research contributions have been broad, including bringing novel investigational therapies for pituitary tumors to our institution, and leading a national effort in pediatric thyroid cancer.

In his new role, Dr. Waguespack will have primary responsibility for oversight of clinical affairs in the department and to guide its rapidly expanding clinical programs. This will include new contributions to the multidisciplinary clinical effort in malignancies of the thyroid and other endocrine glands, growing thyroid cancer survivorship efforts, and inpatient and outpatient consultative activities in bone and mineral disorders, diabetes, and general endocrinology.

Publications:

Santarpia L, Myers JN, **Sherman SI**, Trimarchi F, Clayman GL, El-Naggar AK. Genetic alterations in the RAS/RAF/mitogen-activated protein kinase and phosphatidylinositol 3-kinase/Akt signaling pathways in the follicular variant of papillary thyroid carcinoma. *Cancer* 2010 Jun 15;116(12):2974-83.

Sherman SI, Targeted therapy of thyroid cancer. *Biochem Pharmacol.* 2010 Sep 1;80(5):592-601.

Cabanillas ME, **Waguespack SG**, Bronstein Y, Williams MD, Feng L, Hernandez M, Lopez A, **Sherman SI**, **Busaidy NL**. Treatment

with tyrosine kinase inhibitors for patients with differentiated thyroid cancer: the M. D. Anderson experience. *J Clin Endocrinol Metab.* 2010 Jun;95(6):2588-95.

Morris GS, Grubbs EG, Hearon CM, Gantela S, Lee JE, Evans DB, Holmes HM, **Busaidy NL**, **Jimenez C**, Perrier ND. Parathyroidectomy improves functional capacity in "asymptomatic" older patients with primary hyperparathyroidism: a randomized controlled trial. *Ann Surg.* 2010 May;251(5):832-7.

Hu MI, Lu H, **Gagel RF**. Cancer therapies and bone health. *Curr Rheumatol Rep.* 2010 Jun;12(3):177-85.

Waguespack SG, Rich T, Grubbs E, **Ying AK**, Perrier ND Ayala-Ramirez M, **Jimenez C**. A current review of the etiology, diagnosis, and treatment of pediatric pheochromocytoma and paraganglioma. *J Clin Endocrinol Metab.* 2010 May;95(5):2023-27.

Waguespack SG, Rich TA. Multiple endocrine neoplasia syndrome type 2B in early childhood: long-term benefit of prophylactic thyroidectomy. *Cancer* 2010 May 1;116(9):2284.

Ye L, Santarpia L, **Gagel RF**. The Evolving Field of Tyrosine Kinase Inhibitors in the Treatment of Endocrine Tumors. *Endocr. Rev.* 2010 Jul 6 [Epub ahead of print].

Tuttle RM, Ball DW, Byrd D, Daniels GH, Dilawari RA, Doherty GM, Duh QY, Ehya H, Farrar WB, Haddad RI, Kandeel F, Kloos RT, Kopp P, Lamonica DM, Loree TR, Lydiatt WM, McCaffrey J, Olson JA Jr, Parks L, Ridge JA, Shah JP, **Sherman SI**, **Waguespack SG**, Wang TN, Wirth LJ. Medullary carcinoma. *J Natl Compr Canc Netw.* 2010 May;8(5):512-30.

Sturgis EM, **Sherman SI**. Should papillary thyroid carcinoma be observed?: a word of caution. *Arch Otolaryngol Head Neck Surg.* 2010 May;136(5):444-6.

Sherman SI, Cytotoxic chemotherapy for differentiated thyroid carcinoma. *Clin Oncol (R Coll Radiol)* 2010 Aug;22(6):464-8.

Amhaz HH, Chamoun RB, Waguespack SG, Shah K, McCutcheon IE. Spontaneous involution of Rathke cleft cysts: is it rare or just underreported? *J. Neurosurg.* 2010 Jun;112(6):1327-32.

Incorporating MEN 1 Genetic Testing as a Diagnostic Tool in Clinical Practice

**Elizabeth G. Grubbs, M.D. , Assistant Professor, Department of Surgical Oncology, and
Theresa A. Rich, MS, CGC, Certified Genetic Counselor, Department of Surgical Oncology and Endocrine
Center**

Case Report: A 32 year old man was referred for genetic evaluation due to a history of primary hyperparathyroidism treated surgically 4 years ago as well as a family history of kidney stones in his father, paternal half sister, and paternal uncle. There were no other significant diseases present in the family at the initial evaluation. Since surgery, the patient has been asymptomatic with limited follow-up. His calcium and PTH levels were in the normal range. The patient was asked to have his family members evaluated for hyperparathyroidism. His sister was found with primary hyperparathyroidism and his father was found with normocalcemic hyperparathyroidism.

This vignette describes familial isolated hyperparathyroidism (FIHPT) – there are two confirmed cases of primary hyperparathyroidism in close relatives without any other related diseases. From a genetics standpoint, there are several possible explanations for this observation:

- There is a hereditary condition present in the family – the known hereditary forms of primary hyperparathyroidism include multiple endocrine neoplasia types 1 and 2A (MEN1 and MEN2A) and hyperparathyroidism jaw-tumor syndrome (HPT-JT).
- The two cases of primary hyperparathyroidism in the family occurred coincidentally
- Other – there are thought to be genetic loci associated with susceptibility for primary hyperparathyroidism that have not been fully characterized

There have been several studies assessing the likelihood of MEN1 mutations in FIHPT using genetic testing:

MEN1 Mutation Analysis in Families with Isolated Hyperparathyroidism

Study	Year	MEN1+
Agarwal [1]	1997	0/5
Giraud [2]	1998	0/1
Teh [3]	1998	0/4
Poncin [4]	1999	1/1
Bergman [5]	2000	1/5
Pannett [6]	2003	4/7
Simonds [7]	2004	0/32
Villablanca [8]	2002	2/7
Warner [9]	2004	5/22
Klein [10]	2005	4/24
Ellard [11]	2005	6/17
Cetani [12]	2006	3/7
Mizusawa [13]	2006	1/11
TOTAL		27/143 (18.8%)

Overall, nearly 20% of cases of FIHPT actually have a germline mutation of the MEN1 gene. In most of the MEN1 positive cases, the patients were young at the diagnosis of hyperparathyroidism and had multigland disease.

Risk for a MEN1 mutation is substantially lower for cases of FIHPT with late-onset of HPT (50s and older). For one, HPT associated with MEN1 typically presents prior to age 50, and secondly, it would be unusual for a patient with MEN1 to reach their 50s or older without another feature of the condition in themselves or a close relative. In contrast, young families with HPT may not have reached an age when symptoms of MEN1 are likely to be present, and usually their relatives are also young and also may not have other features of the syndrome.

In the case reported above, the patient was offered MEN1 genetic testing. The rationale for this testing was:

- The family is quite young and may not have manifested other signs of MEN1 yet
- A positive result would significantly impact the patient's medical management
- The result would impact recurrence risks for other members of the family

The patient was provided with genetic counseling and he consented to genetic testing. He was found to have a germline mutation of the MEN1 gene. This result means:

- The patient is at risk for other features of MEN1, including pituitary adenomas, gastroenteropancreatic neuroendocrine tumors (PNETs), and foregut carcinoids as well as recurrent hyperparathyroidism.
- His children each have a 50% risk to inherit the disease. If he plans to have additional children in the future, he would have the option of preimplantation genetic diagnosis or prenatal genetic testing.
- His paternal half-sister with hyperparathyroidism is also likely to have MEN1, and MEN1 was most likely inherited from the patient's father
- Relatives can pursue genetic testing for the mutation found in our patient (available for about \$350) to determine with certainty whether or not they are at increased risk for MEN1-related tumors. Relatives who do not have the MEN1 mutation are not at increased risk for MEN1-related disease and do not need extra screening tests. In addition, they cannot pass the mutation on to their children

An early diagnosis of MEN1-related tumors is expected to reduce morbidity and mortality of the disease by allowing for early diagnosis and treatment of functional tumors (thereby reducing risk for secondary medical conditions cause by functioning tumors) and potentially malignant PNETs (thereby potentially reducing the risk for an advanced cancer). The patient had a complete biochemical evaluation that included measurement of fasting serum prolactin, IGF1, calcium, parathyroid hormone, insulin, proinsulin, 25-OH vitamin D, glucose, gastrin, pancreatic polypeptide, and chromogranin-A. of the laboratory studies were normal. Since many MEN1-related PNETs are non-functional, but clinically significant due to the potential for malignant transformation, the patient also underwent a pancreatic protocol CT scan as well as a chest CT for carcinoid screening.

(Continued on page 7)

(Grubbs and Rich, continued from Page 6)

The patient was found to have a 2.2cm mass in the tail of the pancreas which will be managed surgically.

This case illustrates the utility of MEN1 genetic testing in a young family presenting with only hyperparathyroidism. There were no other diagnostic clues to the presence of the PNET other than the genetic test result. This case also exemplifies the importance of imaging in MEN1 patients even in the absence of suggestive biochemical studies.

References

1. Agarwal, S.K., et al., Germline mutations of the MEN1 gene in familial multiple endocrine neoplasia type 1 and related states. *Hum Mol Genet*, 1997. 6(7): p. 1169-75.
2. Giraud, S., et al., Germ-line mutation analysis in patients with multiple endocrine neoplasia type 1 and related disorders. *Am J Hum Genet*, 1998. 63(2): p. 455-67.
3. Teh, B.T., et al., Mutation analysis of the MEN1 gene in multiple endocrine neoplasia type 1, familial acromegaly and familial isolated hyperparathyroidism. *J Clin Endocrinol Metab*, 1998. 83(8): p. 2621-6.
4. Poncin, J., et al., Mutation analysis of the MEN1 gene in Belgian patients with multiple endocrine neoplasia type 1 and related diseases. *Hum Mutat*, 1999. 13(1): p. 54-60.
5. Bergman, L., et al., Identification of MEN1 gene mutations in families with MEN 1 and related disorders. *Br J Cancer*, 2000. 83(8): p. 1009-14.
6. Pannett, A.A., et al., Multiple endocrine neoplasia type 1 (MEN1) germline mutations in familial isolated primary hyperparathyroidism. *Clin Endocrinol (Oxf)*, 2003. 58(5): p. 639-46.
7. Simonds, W.F., et al., Familial isolated hyperparathyroidism is rarely caused by germline mutation in HRPT2, the gene for the hyperparathyroidism-jaw tumour syndrome. *J Clin Endocrinol Metab*, 2004. 89(1): p. 96-102.
8. Villablanca, A., et al., Involvement of the MEN1 gene locus in familial isolated hyperparathyroidism. *Eur J Endocrinol*, 2002. 147(3): p. 313-22.
9. Warner, J., et al., Genetic testing in familial isolated hyperparathyroidism: unexpected results and their implications. *J Med Genet*, 2004. 41(3): p. 155-60.
10. Klein, R.D., et al., Clinical testing for multiple endocrine neoplasia type 1 in a DNA diagnostic laboratory. *Genet Med*, 2005. 7(2): p. 131-8.
11. Ellard, S., et al., Detection of an MEN1 gene mutation depends on clinical features and supports current referral criteria for diagnostic molecular genetic testing. *Clin Endocrinol (Oxf)*, 2005. 62(2): p. 169-75.
12. Cetani, F., et al., Genetic analyses in familial isolated hyperparathyroidism: implication for clinical assessment and surgical management. *Clin Endocrinol (Oxf)*, 2006. 64(2): p. 146-52.
13. Mizusawa, N., et al., Genetic analyses in patients with familial isolated hyperparathyroidism and hyperparathyroidism-jaw tumour syndrome. *Clin Endocrinol (Oxf)*, 2006. 65(1): p. 9-16.

Wish to make a donation to Endocrine Research?

You can make a huge difference in the lives of those with endocrine tumors and hormonal disorders by donating to our endocrine research funds. New discoveries made for endocrine malignancies can be applied towards other types of cancers. We now have a webpage for your convenience: <http://www.mdanderson.org/education-and-research/departments-programs-and-labs/departments-and-divisions/endocrine-neoplasia-and-hormonal-disorders/endocrine-research.html>.

How to refer a patient to MD Anderson

Online Referrals:

MD Anderson has created an online referral process, myMDAnderson, to help you get your patient into MD Anderson as quickly as possible. You can use myMDAnderson to follow the treatment your patients receive by viewing transcribed reports and accessing your patients' schedules. To qualify for this free service, you must be a licensed, practicing physician. To start a referral through myMDAnderson, please access this portal:

<https://my.mdanderson.org/public/physicians/user/>

Telephone Referrals:

Physician to Physician referrals to the Dept. of Endocrine Neoplasia and H.D., please call 713-792-2841.

To speak to a New Patient Referral Coordinator, please call 713-563-4400.

For Pediatric Referrals (patients less than 18 years of age), please call 713-792-5410.



Introducing the new Multiple Endocrine Neoplasia Specialty Clinic at MD Anderson Cancer Center

The Multiple Endocrine Neoplasia (MEN) Specialty Clinic at MD Anderson is a service dedicated to our patients who have a known or suspected diagnosis of MEN1 or MEN2. We also evaluate relatives who are at risk to inherit MEN1 or MEN2. Features of the clinic include:

- Streamlined and comprehensive medical care by a multidisciplinary team including endocrinologists, endocrine surgeons, oncologists, and diagnostic radiologists. We specialize in the treatment and early detection of MEN-related diseases.
- Supportive services such as nutrition and social work
- Genetic counseling and genetic testing services
- Comprehensive assessment of patients with a questionable diagnosis of MEN1 or MEN2 to provide a more definitive answer.

The mission of the MEN Specialty Clinic is to offer our patients the highest quality in care and expertise in the diagnosis, treatment, and monitoring for MEN-related diseases. Our team works together to provide accurate and efficient evaluations to ensure the best treatment and monitoring plan for each patient.

Established MD Anderson patients should speak with their physician about referral to the clinic. New patients should contact the Endocrine Center's new patient office at 713-563-4400 (or call 713-792-5410 for patients 18 years and younger).

The University of Texas
MD Anderson Cancer Center
Endocrine Neoplasia and Hormonal Disorders - Unit 1461
PO Box 301402
Houston, Texas 77230-1402

NONPROFIT
U.S. POSTAGE
PAID
HOUSTON, TX
PERMIT NO. 7052

Seeking Patients for a Phase II Study:

We are actively recruiting patients for a Phase II Study Evaluating the Efficacy and Safety of Ultratrace Iobenguane I 131 in Patients with Malignant Relapsed/Refractory Pheochromocytoma/Paraganglioma. The Study MIP-1b12b is a multi-center, open-label, single arm trial that is expected to enroll approximately 75 patients to receive two therapeutic doses (500mCi each) of Ultratrace Iobenguane I 131. Patients will be evaluated for efficacy and safety for a 12-month period, then for survival for an additional 4 years.

Ultratrace Iobenguane is a radiopharmaceutical and is a form of Iobenguane I 131 with a very high specific activity that targets tumors of the neuroendocrine system. Iobenguane is a guanethidine derivative structurally resembling norepinephrine, and is a substrate for the norepinephrine transporter (NET).

The primary objective of this study is to evaluate the proportion of study subjects who experience a reduction and/or discontinuation of all antihypertensive medications by at least 50%. This reduction/discontinuation must be sustained for a minimum of six months or two cycles.

The patient must have a documented diagnosis of either pheochromocytoma or paraganglioma that was confirmed with histology or a physician using other supportive data (e.g. abnormal MIBG diagnostic study or elevated tumor markers). He/she must be ineligible for curative surgery for the malignancy or have failed a prior therapy for the tumor, or are not candidates for chemotherapy or other curative therapies. The patient also must have at least one measurable tumor site by CT or MR or Iobenguane I 131 scan and have definitive MIBG tumor avidity. In addition, the patient will not be considered for the study if he or she has New York Heart Association class IV heart failure, cardiac arrhythmia, chronic liver disease, renal dysfunction/impairment, or received prior whole-body radiation therapy or external beam therapy to less than 25% of bone marrow.

The Molecular Insight Pharmaceuticals will pay all transportation costs for study visits for the enrolled patient and a companion. Additional information about the trial including participating sites can be found at: <http://www.clinicaltrials.gov/ct2/show/NCT00874614>.

If you are interested in learning more about this trial or have potential patients that would like to participate in the trial, please contact Camilo Jimenez, MD at 713-792-1977.

Department of Endocrine Neoplasia and Hormonal Disorders Faculty

Steven I. Sherman, M.D., Chair, Professor
and Center Medical Director, Endocrine Center
Naifa L. Busaidy, M.D., Assistant Professor
Rozita Bagheri-Yarmand, Ph.D., Assistant Professor
Maria E. Cabanillas, M.D., Assistant Professor
Gilbert J. Cote, Ph.D., Professor
Robert F. Gagel, M.D., Professor
Mouhammed A. Habra, M.D., Assistant Professor

Mimi I. Hu, M.D., Assistant Professor
Camilo Jimenez, M.D., Assistant Professor
Victor R. Lavis, M.D., Professor
Sara Peleg, Ph.D., Associate Professor
Rena Vassilopoulou-Sellin, M.D., Clinical Professor
Steven G. Waguespack, M.D., Associate Professor
Sai Ching Jim Yeung, M.D., Ph.D., Associate Professor
Anita K. Ying, M.D., Assistant Professor