



Posterior Retroperitoneoscopic Adrenalectomy

THE UNIVERSITY OF TEXAS
MD ANDERSON
CANCER CENTER
Making Cancer History™



Nancy D. Perrier, M.D., F.A.C.S., Associate Professor, Section Chief, Surgical Endocrinology, and Associate Medical Director, Endocrine Multidisciplinary Center

Since its first description in 1992, transabdominal laparoscopic adrenalectomy (LA)^{1, 2} has become the gold standard for the surgical removal of benign adrenal neoplasms. LA is traditionally performed with the patient on his or her side. The posterior laparoscopic approach via the flank with balloon insufflation was introduced shortly thereafter but not met with enthusiasm. In contrast, posterior retroperitoneoscopic adrenalectomy (PRA) is performed with the patient in the prone jackknife position with insufflation pressures nearly twice those of other laparoscopic approaches. Advantages of PRA include direct exposure of the adrenal gland without the need for adjacent organ displacement and improved visualization of and access to the adrenal vein. However, many surgeons feel that the absence of familiar anatomic landmarks with the posterior approach makes the PRA more challenging to learn than the LA.³

The M. D. Anderson Surgical Endocrine Team began performing PRAs in late 2005. The group participated in an organized educational program that involved assisting with a series of cases in Germany followed by a reverse site visit in which Dr. Martin Walz, the renowned expert in PRAs, proctored cases performed here at M. D. Anderson.^{4, 5} Since then, the PRA has become our preferred technique for the removal of benign adrenal tumors that are 6 cm or smaller in diameter and adrenal metastases. The PRA is particularly beneficial for patients who have previously undergone abdominal surgery and those who need bilateral adrenalectomy (e.g., for persistent Cushing's disease). Patients in whom adrenocortical carcinoma is suspected preoperatively based on clinical presentation (size, excess production of multiple hormones) or radiographic findings are not considered candidates for this approach. The 86 cases performed by our team represent the largest experience with PRA to date in the United States.⁶

Operative Technique

After general endotracheal anesthesia is induced

with the patient supine, the patient is placed in a prone jackknife position on a table saddle with an abdominal support device to allow the ventral abdominal wall to hang anteriorly without constraint (Fig 1). The hips and knees are carefully positioned at approximately 90-degree angles relative to the spine and femur.

A 10-mm transverse incision is made just beneath the tip of the 12th rib. The soft tissues are divided sharply, and the retroperitoneal space is entered. Two other trocars (one 10 mm and the other 5 mm) are inserted along the paraspinous musculature and beneath the 11th rib. Pneumoretroperitoneum is created, retroperitoneoscopy is performed, Gerota's fascia is entered, and the superior border of the kidney is identified. The tissue superior to the kidney that contains the lower aspect of the adrenal gland is completely separated from the kidney (Fig 2). The adrenal vein is identified, clipped, and divided (Fig 3).

The 86 PRA operations performed at M. D. Anderson so far (Table 1) represent about three quarters of the laparoscopic adrenalectomies and a third of the adrenalectomies performed at our institution by all surgeons during the past 3 years. More than half of the patients who have undergone PRAs here had a history of prior abdominal surgery, which is considered a relative contraindication to an anterior laparoscopic approach. More than 94% of PRAs attempted have been successfully completed, and there have been no PRA-related deaths. The mean hospital stay is 1.5 days. Postoperative pain and ileus are minimal. Patients are quickly able to tolerate a general diet. Continued on page 2

Table of Contents

Posterior Retroperitoneoscopic Adrenalectomy	Page 1
Upcoming Events	Page 2
Notes from the Endocrine Faculty Team	Page 4
Introducing the New Thyroid Nodule Clinic	Page 4
Systemic Therapy in Adrenocortical Carcinoma	Page 5
Clinical Trials	Page 7
Pediatric Adrenal Tumors	Page 8
The Malignant Pheochromocytoma and Paraganglioma Research Group	Page 8
Announcements	Page 10
New Cancer Survivorship Clinic	Page 10

(Perrier, Continued from Page 1)

Discussion

Posterior retroperitoneal adrenalectomy is a safe operation. Advantages of this approach include the ability to avoid mobilization of the intra-abdominal solid organs (colon, spleen, pancreas, and liver) and to avoid having to deal with intra-abdominal scar tissue and adhesions. These advantages are particularly helpful in patients who have had multiple prior operations.⁷ Moreover, the PRA is confined to the retroperitoneum, penetrates neither the pleural nor the abdominal cavity, and is particularly attractive for patients requiring bilateral adrenalectomy because it eliminates the need for patient repositioning during surgery.

Important steps in the success of the PRA include proper trocar placement, identification and gentle downward retraction of the kidney, and maintenance of the horizon by an experienced assistant controlling the camera. In addition, after the adrenal is separated from the kidney, it is important to identify and divide the adrenal vein while the adrenal gland remains attached superiorly and laterally. Furthermore, the application of relatively high CO₂ insufflation pressures (up to 24 mm Hg) to improve visibility while creating an adequate retroperitoneal working space is essential. The higher CO₂ pressure also tends to tamponade bleeding from small vessels, minimizing blood contamination of the field and improving visibility. This insufflation pressure does not result in clinically evident decreased venous return or cardiac output despite the obvious compression of the inferior vena cava seen when performing a right-sided PRA.^{8,9} The complexities of patient positioning, instrumentation, and anesthesia management for PRAs are minimized by having a dedicated group of specialists, including a dedicated anesthesiologist, provide surgical support; this is particularly important in patients with catecholamine producing tumors.

The PRA requires a mental "reorientation" for the surgeon as the retroperitoneal structures are not commonly visualized from this posterior view. The retroperitoneal space is relatively small, and there are few familiar landmarks. However, once the surgeon becomes comfortable with the procedure, there are clear landmarks to direct the operation. In particular, the upper pole of the kidney, paraspinal muscles, diaphragm, white areolar perirenal tissue, and medial adrenal surface are important landmarks. It is essential that the camera stay focused on the region of the adrenal gland, even before the adrenal is visualized; especially early in a surgeon's experience. Having an experienced assistant control the camera to maintain anatomic perspective and a properly oriented horizon is invaluable. Identification of the adrenal gland buried in the perinephric fat is the major technical difficulty related to PRA and perhaps the one most influenced by the learning curve. If the abundant perirenal fat is haphazardly dissected in an attempt to identify the adrenal gland, the operative field can soon become obscured. It is imperative that the relatively bloodless, avascular plane between the inferior border of the adrenal and the parenchymal surface of the kidney be recognized early in the operation. Identification of the medial surface of the adrenal tumor or gland early in the operation is critical and provides a constant anatomic orientation for further manipulation.

Our mean operating time of 121 minutes (range; 28-226 minutes) for unilateral PRA is comparable to the times reported in our own and other large series of anterior and lateral LAs.^{10,11} The mean hospital stay is also comparable to or shorter than the stays reported for anterior LAs and lateral retroperitoneal adrenalectomies in other series.¹² This is important because a large percentage of functioning tumors often require a few days of medical management prior to hospital discharge (Example:

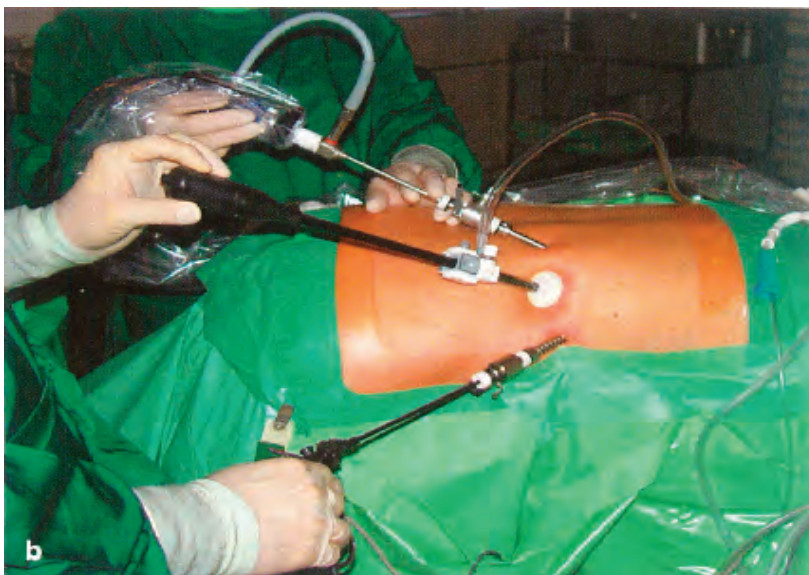

Figure 1
Right sided posterior laparoscopic adrenalectomy. This is a patient in the prone, jackknife position for a right posterior retroperitoneoscopic adrenalectomy. Head is the right of the picture. Three port sights are used. Two are 10 mm and one is 5 mm. The incisions are below the costal margin of the retroperitoneal structures. Visualization is through a 30 scope.

Upcoming Events

AACE 18th Annual Meeting and Clinical Congress
May 13-17, 2009. Houston, TX. (www.aace.com)

The Endocrine Society
ENDO 2009, June 10-13, 2009. Washington, DC. (www.endo-society.org)

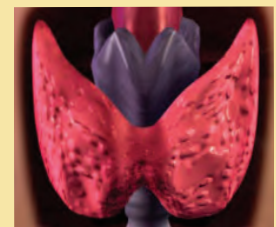
World Congress on Thyroid Cancer, August 6-10, 2009. Toronto, Canada. (<http://www.thyroid2009.ca/>)

80th Annual Meeting of the American Thyroid Association, Sept. 23-27, 2009. The Breakers Hotel, Palm Beach, FL. (http://www.thyroid.org/ann_mtg/2009_80th/index.html)

North American Neuro-Endocrine Tumor Society Annual Conference
Diagnosis & Management Strategies: A Multidisciplinary Approach
October 2-3, 2009
Charlotte Marriott City - Charlotte, North Carolina
(Additional information to be announced later)

ThyCa's 12th International Thyroid Cancer Survivor's Conference, Oct. 16,18, 2009. Boston, MA. (<http://www.thyca.org/ConfFlyer2009.pdf>)

Third Annual Thyroid Neoplasms Conference, Oct. 21-24, 2009
El Dorado Hotel, Sante Fe, NM
(<http://www.mdanderson.org/conferences>)



(Perrier, continued from page 2)

patients with long-standing Cushing's disease require steroid tapers; those with pheochromocytoma receive high-dose alpha and beta blockade). We believe that the overall advantages that PRA offers to the patient--minimal discomfort, early return of bowel function, and early discharge--are difficult to achieve with other techniques, especially after the learning curve for PRAs has been conquered.

Because the risks of malignancy and rupture increase with tumor size and because larger tumors are more difficult to manipulate in the limited retroperitoneal space, PRAs should be reserved for patients believed to have benign primary adrenal neoplasms, 6 cm or smaller and for patients with relatively small metastases involving the adrenal gland. We avoid PRAs in the morbidly obese.⁹

The faculty surgeons involved in this operation are endocrine surgeons who have a large experience with open (anterior and posterior) adrenalectomy as well as conventional transabdominal LAs. The system employed for the transfer of this new operative technique to M. D. Anderson--training under an expert at his institution and then a visit by the expert to our institution--can serve as a model for those interested in deploying other emerging technologies.

In conclusion, the surgical endocrinology team believes that the PRA is a safe and attractive option for minimally invasive adrenalectomy. It can be successfully performed in patients with functioning or non-functioning adrenal tumors. Proper patient positioning, optimal trocar placement, high-pressure CO2 insufflation, and early identification of the bloodless plane are all critically important. The ability to visit a center with expertise in the technique is crucial to successfully adopting

PRAs. Because PRAs provides direct access to the adrenal glands, it may be superior to anterior and lateral LAs in some patients with benign adrenal tumors or small metastases. Which patients are the best candidates for PRA will likely be surgeon dependent. In our practice, PRAs has rapidly become the approach of choice for the majority of patients who require unilateral or bilateral adrenalectomy.

For further information please contact Surgical Endocrinology, 713-794-1345

Table 1. Patient and Tumor Characteristics for the First 86 Patients Who Underwent PRA at M. D. Anderson

Characteristic	No. of Patients (%)
Male	37 (43)
Female	49 (57)
Functioning primary adrenal neoplasm	59 (69)
Conn's syndrome	15
Cushing's disease	6
Cushing's syndrome	13
Virilizing syndrome	2
Pheochromocytoma	23
Nonfunctioning primary adrenal neoplasm	10 (12)
Metastasis	17 (20)
Lung cancer	7
Melanoma	5
Breast cancer	2
Other cancer	3
Unilateral	80 (93)
Left	53
Right	27
Bilateral	6 (7)

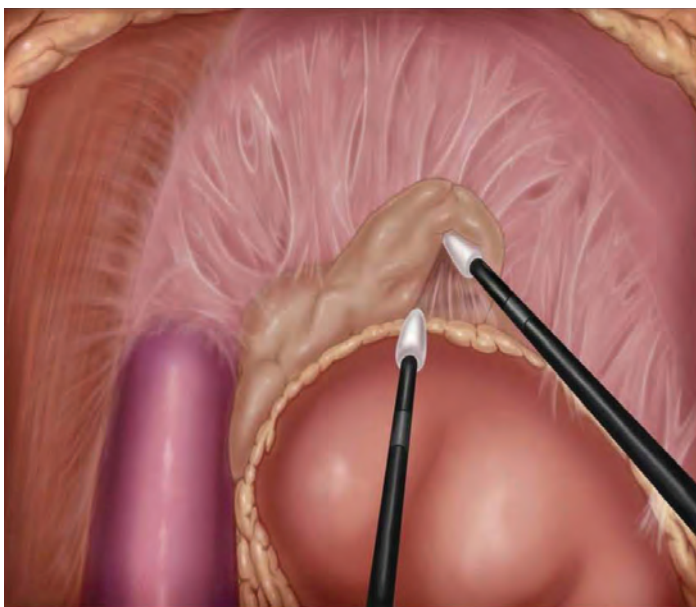


Figure 2
Right-sided PRA. Illustration shows the elevation of the inferior border of the adrenal gland while downward pressure on the right kidney is maintained.

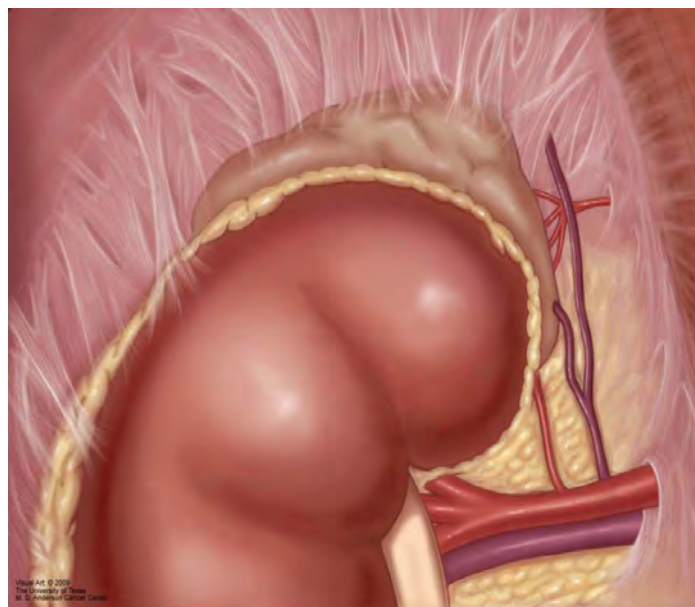


Figure 3
Left-sided PRA. Illustration shows the left adrenal gland with the left adrenal vein and diaphragmatic vein branching off of the left renal vein.

ENDOPERSPECTIVES® is a quarterly publication of the Department of Endocrine Neoplasia and Hormonal Disorders at The University of Texas M. D. Anderson Cancer Center.

Chair

Steven I. Sherman, M.D.

Department Administrator

Carol Atwood, M.A., F.A.C.H.E.

Editor

Charles Stava, M.S.H.A.

Newsletter Committee Members

- Carol Atwood, M.A., F.A.C.H.E.
- Mimi I. Hu, M.D.
- Lorraine Medina
- Linda Roden, M.B.A
- Lea S. Tatar, M.Ed.
- Steven G. Waguespack, M.D.

If interested, please send submissions to Charles Stava, cstava@mdanderson.org. We reserve the right to edit for length, content, and style.

Department of Endocrine Neoplasia and HD website: <http://www.mdanderson.org/departments/endocrinology/>

(Perrier, continued from page 3)

References:

1. Gagner M, Lacroix A, Bolte E. Laparoscopic adrenalectomy in Cushing's Syndrome and pheochromocytoma. *N Engl J Med* 1992; 327(14):1033.
2. Schlunkert RT, van Heerden JA, Grant CS, et al. Laparoscopic left adrenalectomy for aldosteronoma: early Mayo Clinic experience. *Mayo Clin Proc* 1995; 70(9):844-6.
3. Demeure MJ, Jordan M, Zeihen M, Wilson SD. Endoscopic retroperitoneal right adrenalectomy with the patient in the lateral decubitus position. *Surg Laparosc Endosc* 1997; 7(4):307-9.
4. Walz MK, Alesina PF, Wenger FA, et al. Posterior retroperitoneoscopic adrenalectomy—results of 560 procedures in 520 patients. *Surgery* 2006; 140(6):943-50.
5. Walz MK, Peitgen K, Walz MV, et al. Posterior retroperitoneoscopic adrenalectomy: lessons learned within five years. *World J Surg* 2001; 25(6):728-34.
6. Perrier ND, Kenamer DL, Bao R, Jimenez C, Grubbs EG, Lee JE, Evans DB. Posterior retroperitoneoscopic adrenalectomy (PRA): Preferred technique for removal of benign tumors and isolated metastases. *Ann Surg* 2008; 248(4): 666-74.

7. Hudson PB. An extrapleural thoracolumbar surgical approach for adrenalectomy and for radical retroperitoneal dissection. *Ann Surg* 1954; 139(1):44-51.
8. Giebler RM, Walz MK, Peitgen K, Scherer RU. Hemodynamic changes after retroperitoneal CO2 insufflation for posterior retroperitoneoscopic adrenalectomy. *Anesth Analg* 1996; 82(4):827-31.
9. Giebler RM, Behrends M, Steffens T, et al. Intraperitoneal and retroperitoneal carbon dioxide insufflation evoke different effects on caval vein pressure gradients in humans: evidence for the starling resistor concept of abdominal venous return. *Anesthesiology* 2000; 92(6):1568-80.
10. Lin Y, Li L, Zhu J, et al. Experience of retroperitoneoscopic adrenalectomy in 195 patients with primary aldosteronism. *Int J Urol* 2007; 14(10):910-3.
11. Walz MK, Petersenn S, Koch JA, et al. Endoscopic treatment of large primary adrenal tumours. *Br J Surg* 2005; 92(6):719-23.
12. Duh QY, Siperstein AE, Clark OH, et al. Laparoscopic adrenalectomy. Comparison of the lateral and posterior approaches. *Arch Surg* 1996; 131(8):870-5; discussion 875-76.

Notes from the Endocrine Faculty Team

Honor and Recognition:

A big round of applause to **Victor R. Lavis, MD, Steven I. Sherman, MD, and Steven G. Waguespack, MD** for being listed in the eighth issue of the prestigious 'America's Top Doctors' guide by Castle Connolly Medical LTD.

Libero Santarpia, MD, PhD, was awarded the 2008 ATA ThyCa Grant - Medullary Thyroid Cancer. The title of his grant is Identification of microRNA (miRNA) Target Genes in Human Medullary Thyroid Cancer: A Specific Role of miRNAs to Promote Invasion and Metastasis.

Publications:

Waguespack SG, Sherman SI, Williams MD, Clayman GL, Herzog CE. The successful use of sorafenib to treat papillary thyroid carcinoma. *Thyroid* 2009 April; 19(4):406-12.

Santarpia L, Habra MA, Jimenez C. Malignant Pheochromocytoma and Paragangliomas: Molecular Signaling Pathways and Emerging Therapies. *Horm Metab Res*. 2009 Apr 2. [Epub ahead of print].

Habra MA, Jimenez C, Huang SC, **Cote GJ**, Murphy WA Jr, **Gagel RF**, Hoff AO. Expression analysis of fibroblast growth factor-23, matrix extracellular phosphoglycoprotein, secreted frizzled-related protein-4, and fibroblast growth factor-7: identification of fibroblast growth factor-23 and matrix extracellular phosphoglycoprotein as major factors involved in tumor-induced osteomalacia. *Endocr Pract*. 2008 Dec;14(9):1108-14.

Anita K, Ying, MD, received a certificate of completion for the Clinical Safety and Effectiveness Program.

Steven I Sherman, MD, received the Naguib Samaan Distinguished Professorship in Endocrinology. The endowed professorship was named in honor of Naguib Samaan, MD, who served M. D. Anderson from 1969 to 1991 and was appointed as the institution's first chief of endocrinology.

Weaver S, Doherty DB, **Jimenez C**, Perrier ND. Peer-Reviewed, Evidence-Based Analysis of Vitamin D and Primary Hyperparathyroidism. *World J Surg*. 2009 Mar 24. [Epub ahead of print].

Perrier ND, Edeiken B, Nunez R, Gayed I, **Jimenez C, Busaidy N**, Potylchansky E, Kee S, Vu T. A novel nomenclature to classify parathyroid adenomas. *World J Surg*. 2009 Mar;33(3):412-6.

Jimenez C, Cabanillas ME, Santarpia L. Jonasch E, Kyle KL, Lano EA, Matin SF, Nunez RF, Perrier ND, Phan A, Rich TA, Shah B, Williams MD, **Waguespack SG**. Use of the tyrosine kinase inhibitor sunitinib in a patient with von Hippel-Lindau disease: targeting angiogenic factors in pheochromocytoma and other von Hippel-Landau disease-related tumors. *J Clin Endocrinol Metab*. 2009 Feb;94(2):386-91. Epub 2008 Nov 18.

Introducing the New Thyroid Nodule Clinic

Do you need a Resource for a Suspicious Thyroid Nodule?



Thyroid nodules are fairly common, representing the most common endocrine problem in the United States, but effective evaluation is extremely important to rule out thyroid cancer.

Dr. Naifa Busaidy, Director of the new Thyroid Nodule Clinic now open at M. D. Anderson Cancer Center says, "The clinic serves as a resource for our physicians and all patients with thyroid nodules. We want to be a part of your team in providing an exceptional experience for the community physician and their adult and pediatric patients.

Getting a rapid and accurate diagnosis in one place at one time for a patient anxious about whether or not they might have cancer, improves the experience for all those involved. The experienced multidisciplinary team of endocrinologists, surgeons, mid-levels, cytopathologists radiologists and ultrasonographers at M. D. Anderson are here to help you. We also have two pediatric endocrinologists who can evaluate pediatric patients of all ages.

All patients receive within one day:

- Consultation with a thyroid specialist
- Thyroid ultrasound
- Thyroid biopsy, if needed
- Multidisciplinary conference to discuss treatment options, if needed.

The Thyroid Nodule Clinic is located inside the Endocrine Center at M. D. Anderson Cancer Center at 1515 Holcombe in Houston, Texas.

For more information or to refer a patient for an appointment:

New Patient Referral Coordinators: 713-563-4400, and 713-792-5410 for patients under 18 years of age.

Physician to Physician Referrals: 713-792-2841

Online Referrals: <https://my.mdanderson.org/>

Systemic Therapy in Adrenocortical Carcinoma



Mouhammed Amir Habra, M.D., FACP, FACE, Assistant Professor, Department of Endocrine Neoplasia and Hormonal Disorders

Adrenocortical carcinoma (ACC) is a rare disease with an estimated prevalence of 4-12 cases per million. In general it carries poor prognosis based on the extent of disease at the time of initial diagnosis. The 5-year overall disease specific survival ranges from 82% for stage I disease (tumor limited to the adrenal gland and measures less than 5 cm) to 13% for stage IV defined

as having distant metastases.¹ In addition, hormonal overproduction is also found in 50-60% of patients, especially in pediatric cases.

To date, three hereditary syndromes are associated with increased incidence of adrenocortical carcinoma including Li-Fraumeni (germline P53 mutation), Beckwith-Wiedemann syndrome (mutation or deletion of imprinted genes within the chromosome 11p15.5 region), and rarely, multiple endocrine neoplasia type 1 (mutated menin gene on chromosome 11q13).

In patients with Beckwith-Wiedemann Syndrome, the abnormal imprinting of the 11p15.5 locus results in overexpression of insulin like growth factor-2 (IGF-2) and reduced expression, and cyclin-dependent kinase inhibitor 1C (CDKN1C) and H19 genes. IGF-2 signals through IGF-1 receptor (IGF-1R) can cross-react with insulin receptors. CDKN1C functions as a cell cycle regulator and its loss in ACC likely leads to uncontrolled cell division and proliferation. There is also a molecular link between P53 mutations and IGF-2 overexpression.

Surgery represents the best treatment option in ACC however, not all cases are candidates for surgery considering that almost 50% of patients present with evidence distant metastases or inoperable local invasion at the time of initial diagnosis.

Despite radical surgery in selected cases, many patients develop local or distant metastases requiring systemic therapy at some point of their disease course.

Current options for systemic therapy range from mitotane alone, mitotane in combination with traditional chemotherapy, or research protocols studying emerging targeted therapies.

In addition, ACC cases associated with hormonal overproduction need special attention and management to reduce the morbidity related to hormonal excess syndromes (mainly Cushing's syndrome and hyperaldosteronism).

I. Endocrine Therapy

Retrospective evidence suggests increasing frequency of infections in patients with ACC and cortisol overproduction who had primary treatment to their tumor before controlling Cushing's syndrome. Various drugs have been in use to block production of steroids or antagonize steroid action at a receptor level.

Inhibitors of Steroid Synthesis

Ketoconazole: Ketoconazole is an antifungal medication that inhibits adrenal and gonadal steroids biosynthesis by interfering with the final step in steroidogenesis (11 β -hydroxylase) and blocking cholesterol conversion to pregnenolone mediated by cholesterol side chain cleavage enzyme. Ketoconazole is also a potent inhibitor of mitochondrial P450 enzymes which leads to significant and potentially dangerous drug interactions to be added to its known hepatotoxicity.

Metyrapone: Metyrapone was initially used as a diagnostic tool to check the integrity of the hypothalamic-pituitary-adrenal axis. Me-

tyrapone blocks the final step in cortisol production (11 β -hydroxylase) and can be used to treat other causes of endogenous Cushing's syndrome.

Compensatory increase in androgens synthesis can occur as more substrates become available for sex hormone production resulting in hirsutism and virilization in female patients. Metyrapone therapy is often combined with physiologic steroid replacement as a safety precaution against acute adrenal insufficiency. Metyrapone has limited availability and currently obtained directly from the manufacturer to be used for selected cases.

Corticosteroid Receptor Antagonists

RU 486 (mifepristone) is a potent progesterone receptor antagonist that is approved for medical termination of early pregnancy with investigational use in unresectable meningioma. It also antagonizes glucocorticoid receptors which makes it potentially effective in the treatment of Cushing's syndrome. Phase III clinical study is currently evaluating the use of mifepristone in the treatment of Cushing's syndrome. In contrast to steroid synthesis blockers, the effects of mifepristone can not be monitored by cortisol or ACTH measurement and clinically assessment is essential to look for signs and symptoms of adrenal insufficiency that may require drug discontinuation and suprphysiologic steroid dose rescue to overcome receptor blockade.

Mineralocorticosteroid receptor blockers

Spironolactone and eplerenone: Primarily antagonize aldosterone by blocking mineralocorticosteroid receptors. Spironolactone has anti-androgen effects while eplerenone seems to have a more selective role to block aldosterone. Mainly used in the treatment of hypertension alone or in combination with other antihypertensive medications, in liver cirrhosis, and congestive heart failure. ACC patients with hyperaldosteronism often need high doses to block the effect of aldosterone and correct the associated hypokalemia and hypertension.

II. Systemic Chemotherapy

Cytotoxic treatment is often reserved for patients with symptoms related to their cancer, progressive disease, or other poor prognostic factors associated with primary tumor or its metastases. Traditionally, ACC has been viewed as being relatively resistant to chemotherapy as it overexpresses multi drug resistance gene (MDR-1).

Single Agent Systemic Chemotherapy

Mitotane: Mitotane (o,p'-DDD) is a derivative of the insecticide DDT that was reported to induce adrenal cortex destruction mainly in zona reticularis. Based on these initial observations, the use of mitotane was studied in the clinical management of ACC. In addition, mitotane blocks steroidogenesis by inhibiting 11 β -hydroxylase and cholesterol side chain cleavage and thus can induce adrenal insufficiency if not combined with concomitant steroid replacement. Most patients need high dose steroid replacement as mitotane increases steroid binding globulin and accelerates the metabolism of steroid hormones. Similar changes are also observed in patients receiving thyroid hormone replacement and often need levothyroxine dose adjustment.

Main side effects of mitotane exposure include gastrointestinal symptoms (nausea, vomiting, diarrhea, anorexia), neurological symptoms (insomnia, depression, confusion, tremors, ataxia), hyperlipidemia, platelets dysfunction, in addition to above mentioned changes in steroid and thyroid hormone metabolism. It is unclear if some of these side effects are related to co-existing adrenal insufficiency that can be treated with increasing steroid replacement dose.

Continued on Page 6

(Habra, continued from page 5)

Our standard approach is to monitor serum electrolytes as well as adrenocorticotropin hormone (ACTH) levels to allow titrating steroid replacement with a goal to keep ACTH levels near low normal levels.

It is also very important to achieve therapeutic plasma mitotane levels (14-20 mg/L) considering the data linking therapeutic mitotane level with objective tumor and hormonal response to therapy. In addition, severe neurologic toxicity was noticed only with patients with levels exceeding the therapeutic range.²

Mitotane is given when surgery is not possible, after incomplete resection, in combination with chemotherapy for metastatic disease, and in selected cases as adjuvant therapy after seemingly complete resection. The exact duration of mitotane therapy in the adjuvant setting is not clear but often patients receive 2-5 years of therapy that must be frequently adjusted based on mitotane levels and side effect profile. The overall tumor response rate to mitotane therapy is about 25-30% but there is conflicting literature about its effect on overall survival. However, there is retrospective evidence that achieving therapeutic plasma mitotane level of 14mg/L or higher is associated with better outcome and possibly improved survival.

The concept of mitotane as adjuvant therapy after complete resection was revisited recently in a multicenter retrospective study evaluating 177 patients from various centers in Italy and Germany. Based on the authors' findings, adjuvant mitotane resulted in improved recurrence free survival (42 months compared to 25 and 10 months in two control groups) and improved overall survival (median overall survival 110 months in the mitotane group, as compared with 52 and 67 months in control groups).³ The inherent deficiencies of retrospective reviews have resulted in the design of international prospective study (ADIUVO Study) to evaluate the role of adjuvant mitotane in ACC patients with low and intermediate risk for recurrence.

Gossypol: Gossypol is a plant toxin extracted from cottonseeds with anti proliferative properties mediated via uncoupling of oxidative phosphorylation and destruction of mitochondria mostly in the adrenal cortex.^{4,5} It also blocks steroids production by inhibiting cholesterol side-chain cleavage and 11 β -hydroxylation.⁶ Preliminary studies in cell cultures and nude mice showed inhibitory effect on human ACC SW-13 cells.⁷ Experience in humans is limited to one published report that demonstrated durable partial response in 3 out of 18 patients who otherwise failed other therapies.⁸ A phase II clinical study is currently evaluating gossypol acetic acid in patients with recurrent, metastatic, or unresectable ACC (NCT00848016).

Suramin: Suramin is an antitrypanosomal medication with potential antineoplastic activity as it blocks the binding of several growth factors to their receptors. It also accumulates in the adrenal cortex and blocks steroidogenesis. The initial report of using suramin in ACC reported one case that failed mitotane and subsequently received suramin and had sudden death six weeks after discontinuing suramin.⁹

In a small study including 9 patients with metastatic ACC, suramin therapy achieved short lived disease stabilization or partial response in 5/9 patients without affecting steroids production. Two patients died likely related to suramin toxicity considering its narrow therapeutic window.¹⁰

Doxorubicin: Only limited durable response was noted in earlier studies using doxorubicin as a single agent. In the ECOG trial that included 52 ACC patients out of whom 16 received doxorubicin monotherapy as first line treatment and resulted in 19% partial response. In another subgroup of patients, doxorubicin monotherapy was ineffective as a second line therapy in patients who failed mitotane earlier.¹¹

Irinotecan (CPT-11): No objective response was reported when irinotecan was evaluated prospectively as a single agent to treat adrenocortical carcinoma.¹²

Multiple-Agent Chemotherapy

Considering the limited success of single-agent chemotherapy in ACC, studies often combined two or more systemic agents aiming to increase efficacy and reduce the toxic side effects seen while giving high dose single agent regimens.

Most of the published studies combine mitotane with other systemic chemotherapy agents as mitotane reduces the expression of multi-drug resistance P-glycoprotein.

Cisplatin-based Regimens: Cisplatin alone or in combination with mitotane was associated with 30% response rate in 37 ACC patients but with moderate to severe toxicity.¹³

The addition of cisplatin and doxorubicin, to cyclophosphamide in a small study involving 11 patients with ACC resulted in a partial response rate of about 20% which was not far from the responses noted earlier in single agent protocols.¹⁴

The combination of vincristine, cisplatin, teniposide, and cyclophosphamide (OPEC) was evaluated in 11 ACC patients who previously failed mitotane/streptozocin therapy and resulted in 2 year-overall survival of 82%. Most of the evaluable patients had stable disease.¹⁵

Taxotere with cisplatin: A phase II trial is currently open in Denmark and will include ACC patients with inoperable disease to evaluate the response rate to this combination protocol (NCT00324012).

The combination of cisplatin and etoposide was evaluated in 18 ACC patients (14 with mitotane). The overall response approached 33% (3 complete response and 3 partial response).¹⁶ Subsequent study evaluated the cisplatin/etoposide combination in 45 ACC patients but objective responses were seen in only 11% of the patients (13% when mitotane was added for progressive disease).¹⁷

The combination of etoposide, doxorubicin, and cisplatin (EDP) with mitotane in 28 ACC patients showed an overall objective response rate of 54 % (complete response in 2 patients and partial response in 13 patients). Only 3 patients discontinued treatment due to toxicity. Adding mitotane increased the gastrointestinal and neurological toxicity and only 9 patients took mitotane at the planned dose and mitotane levels were not monitored in this study.¹⁸ A subsequent report from the same group in Italy included 72 ACC patients with unresectable disease and reported similar findings of overall response approaching 50 % (5 CR and 30 PR). One patient died secondary to the treatment related toxicity. This regimen also allowed subsequent surgical resection in 10 patients.¹⁹

Streptozocin with Mitotane: The initial report about this combination involved 3 patients with ACC. Two patients had neoadjuvant therapy and later had surgical resection and 1 patient had metastatic disease and showed regression of lymph node and lung metastases lasting more than 6 years.²⁰ A later phase II study involved 40 ACC patients who were given intravenous streptozocin with mitotane showed improved overall survival. Overall response rate was about 36% and the overall five year survival was 32%.²¹

Currently, an international phase III study (FIRM-ACT) is the first clinical trial ever conducted mainly in Europe randomizing ACC patient to either EDP-mitotane or streptozocin-mitotane regimens with a focus on overall survival and quality of life, time to progression, response rate and, response duration.

A recent review compared different regimens in 57 patients who received first-line systemic chemotherapy in our institution between 1980 and 2000. The regimens included mitotane alone (n=12), cisplatin and etoposide (n=16), mitotane with cisplatin and etoposide (n=11), mitotane with other cytotoxics [gemcitabine (n=2), cisplatin (n=1), carboplatin with paclitaxel (n=1) or doxorubicin with vincristine and etoposide (n=1)], cisplatin and etoposide with other cytotoxics [doxorubicin (n=1), doxorubicin, and mitotane (n=1), and ifosfamide (n=1)], and other miscellaneous cytotoxics [gemcitabine (n=3), paclitaxel (n=3), cisplatin/doxorubicin/cyclophosphamide (n=2), cisplatin/doxorubicin/ifosfamide (n=1), and doxorubicin (n=1)]. There was no clear advantage of any particular regimen and no significant differences in overall survival among groups.²²

Continued on Page 7

(Habra, continued from page 6)

III. Molecular Targets and Emerging Therapy

The exact etiology of adrenocortical carcinoma is mostly unknown as most cases are sporadic and lack unifying risk factors. Experience is still very limited amongst targeted therapies in patients with ACC despite recent advances in exploring activated pathways in ACC.

MDR-1 Inhibitors: P-glycoprotein, a product of the multi drug resistance -1 gene (MDR-1), is associated with a resistance to multiple chemotherapy agents thus increasing the efflux of medications. Mitotane increased intracellular accumulation of chemotherapy drugs by the antagonizing of P-glycoprotein in adrenocortical carcinoma cells. These findings suggest that the expression of P-glycoprotein in adrenocortical carcinoma is not related to clinical manifestations, steroid production, histological index or response to mitotane therapy.²³

Phase I study in patients with advanced malignancies reported that second-generation P-glycoprotein antagonist (valsopodar) in combination with vinblastine showed reduced dosing of vinblastine while valsopodar dose was increased.²⁴

The use of mitotane as a P-glycoprotein inhibitor in combination with doxorubicin, vincristine, and etoposide in 36 patients with metastatic ACC resulted in 22% response rate.²⁵

Tariquidar, a third generation selective P-glycoprotein inhibitor is currently used in phase II trials in combination with mitotane, doxorubicin, vincristine, and etoposide plus surgery in ACC patients (NCT00073996).

Epidermal growth factor receptor (EGFR) inhibitors: Erlotinib combined with gemcitabine as a salvage therapy in 10 patients with advanced ACC had very limited efficacy and 9 out of 10 patients died within 6 months period with very advanced ACC.²⁶

Phase II study using other EGFR inhibitor (gefitinib) in patients with unresectable ACC (NCT00215202) has been completed but the results have not been published yet.

Vascular endothelial growth factor receptor (VEGFR) inhibitors: Sunitinib is an oral tyrosine kinase inhibitor with activity against VEGFR, RET, platelet-derived growth factor receptors (PDGF-R), flt-3, and c-KIT. The use of sunitinib has been reported recently in one patient with ACC who had partial response for about 8 months after failing mitotane based chemotherapy.²⁷ Phase II clinical trial (NCT00453895) is underway in Europe to evaluate sunitinib in refractory adrenocortical carcinoma (SIRAC).

Sorafenib is another oral, small molecule tyrosine kinase inhibitor

with activity against VEGFR, PDGFR, BRAF, and c-kit. a Phase II study (NCT00786110) combining sorafenib with weekly paclitaxel in locally advanced or metastatic ACC not amenable to complete surgical resection is showing progress to cytotoxic chemotherapy.

Insulin like growth factor 1 receptor (IGF-1R) inhibitors: Insulin-like growth factors (IGF) 1 and 2 are expressed in the adrenal cortex and affect cellular proliferation and hormonal synthesis in a paracrine/autocrine fashion. IGF-2 has been repeatedly shown to be the most up-regulated transcript in adult and pediatric ACC patients in association with reduced expression of H19 and CDKN1, which are also located on the same genetic locus(11p15.5).²⁸ IGF-2 signaling is mediated through its interaction with IGF-I receptors, while the IGF-2 receptor acts as a decoy receptor to sequester IGF-2.

Earlier in-vitro studies with IGF-1R inhibitor (NVP-AEW541) showed dose dependent inhibition of ACC cell line proliferation.²⁹

IMC A-12 is a monoclonal antibody that inhibits IGF-1R. Preclinical in-vitro and animal studies showed reduced ACC cell proliferation induced by IMC A-12 that was further augmented when combined with mitotane.³⁰

Phase I/II clinical study (NCT00810537) is in progress at the present to evaluate the effect of IMC A-12 alone or in combination with mitotane in ACC patients.

References:

1. Fassnacht M, Johanness S, Quinkler M, Bucsky P, Willenberg HS, Beuschlein F, Terzolo M, Mueller HH, Hahner S, Allolio B 2009 Limited prognostic value of the 2004 International Union Against Cancer staging classification for adrenocortical carcinoma: proposal for a Revised TNM Classification. *Cancer* 115(2):243-50.
2. Baudin E, Pellegriti G, Bonnay M, Penfornis A, Laplanche A, Vassal G, Schlumberger M 2001 Impact of monitoring plasma 1,1-dichlorodiphenildichloroethane (o,p'DDD) levels on the treatment of patients with adrenocortical carcinoma. *Cancer* 92(6):1385-92.
3. Terzolo M, Angeli A, Fassnacht M, Daffara F, Tauchmanova L, Conton PA, Rossetto R, Buci L, Sperone P, Grossrubatscher E, Reimondo G, Bollito E, Papotti M, Saeger W, Hahner S, Koschker AC, Arvat E, Ambrosi B, Loli P, Lombardi G, Mannelli M, Bruzzi P, Mantero F, Allolio B, Dogliotti L, Berruti A 2007 Adjuvant mitotane treatment for adrenocortical carcinoma. *N Engl J Med* 356(23):2372-80.
4. Cuellar A, Ramirez J 1993 Further studies on the mechanism of action of gossypol on mitochondrial membrane. *Int J Biochem* 25(8):1149-55.
5. Le Blanc M, Russo J, Kudelka AP, Smith JA 2002 An in vitro study of inhibitory activity of gossypol, a cottonseed extract, in human carcinoma cell lines. *Pharmacol Res* 46(6):551-5.
6. Cuellar A, Diaz-Sanchez V, Ramirez J 1990 Cholesterol side-chain cleavage and 11 beta-hydroxylation are inhibited by gossypol in adrenal cortex mitochondria. *J Steroid Biochem Mol Biol* 37(4):581-5.
7. Wu YW, Chik CL, Knazek RA 1989 An in vitro and in vivo study of antitumor effects of gossypol on human SW-13 adrenocortical carcinoma. *Cancer Res* 49(14):3754-8.

For a complete list of references, please email the newsletter editor at this address: cstava@mdanderson.org.

Clinical Trials

Phase II trial of Sunitinib (SU11248) in Iodine-131 refractory, unresectable differentiated thyroid cancers and medullary thyroid cancers

The goal of this clinical research study is to learn if sunitinib can help control thyroid cancer that has spread outside the thyroid. The safety of this drug will also be studied. Patients must have histologically or cytologically conformed papillary, follicular, or Hurthle cell carcinoma; or medullary thyroid carcinoma. The patient's disease must have progressed despite treatment with iodine-131 therapy or they cannot be candidates for iodine-131 therapy, as well as their malignancy could not be removed by surgery. They must have radiographically or biochemically measurable disease, and cannot have received prior receptor tyrosine kinase inhibitors or external beam radiation to the tumor region.

For more information, please contact Cheryl Mize, Research Nurse, at 1-713-792-2841 for further information.

A multicenter, randomized, blinded study to assess safety and efficacy of pasireotide LAR vs. octreotide LAR in patients with active acromegaly

This goal of this clinical research study is to compare an investigational treatment for acromegaly against the standard treatment for acromegaly. Pasireotide long-acting release (LAR), which is also known as som230 LAR, will be compared against Sandostatin® LAR (octreotide LAR). Researchers want to learn if pasireotide LAR can help to control acromegaly. The safety of pasireotide LAR will also be studied.

This is open to patients with active acromegaly demonstrated by a lack of suppression of GH nadir to < 1 µg/L after an oral tolerance test with 75 g of glucose (OGTT) (not applicable for diabetic patients) or a mean GH concentration of a 5-point profile within a 2 hour time period of > 5 µg/L AND an elevated circulating IGF-1 concentration (age and sex adjusted). Patients who received pasireotide (SOM230) prior to randomization or have had pituitary irradiation within the last 10 years may not be considered.

For more information, please contact Pat Degen, Research Nurse Supervisor, at 1-713-792-2396.

For information on other clinical trials conducted at M. D. Anderson Cancer Center, please visit: http://www.mdanderson.org/Cancer_Pro/CS_Resources/display.cfm?id=562561A1-751F-11D4-AEBD00508BDCCE3A&method=displayFull. For information on other clinical trials conducted at other institutions, please visit: <http://www.clinicaltrials.gov/>

Pediatric Adrenal Tumors



Anita K. Ying, M.D., Assistant Professor, Department of Endocrine Neoplasia and Hormonal Disorders

Adrenal tumors are rare in the pediatric population, but comprise the majority of extracranial solid tumors. Adrenocortical tumors (ACT) make up 1.8% of all adrenal neoplasms and have a U.S. incidence of 0.2-0.3 cases/million/year.¹ ACT can be benign or malignant pathologically, but this does not always correlate with the clinical behavior of the tumors. ACT tends to be present at a young age (median age 3-4 years) and have a female predominance.¹ Also, in >90% of cases, ACT is functional, usually over-producing androgens and/or glucocorticoids.¹ Genetic syndromes can be associated with ACT in children, including Li-Fraumeni syndrome, Beckwith-Wiedemann syndrome (BWS), and hemihypertrophy outside of BWS.

The diagnosis is often delayed as in adults. It may present as an abdominal mass or pain, or as virilization in the young child or Cushing's syndrome in the adolescent. Due to the concomitant endocrinopathy, diagnosis of ACT is usually made by clinical presentation and a hormonal profile. CT and/or MRI may help distinguish between benign and malignant neoplasm and differentiate ACT from other adrenal tumors. Biopsy of an adrenal mass is not helpful and is generally contraindicated due to the possibility of tumor seeding along the needle tract.

Most children with adrenal neoplasms should undergo surgical re-

section since there is a higher rate of cancer in these tumors, and complete resection can be curative.² Open adrenalectomy by an experienced surgeon is the method of choice if ACT is suspected due to increased risk of capsule rupture and tumor spillage. Laparoscopic adrenalectomy has been used with success in pediatric patients for tumors known to be benign pre-operatively. First-line medical therapy for malignant ACTs includes mitotane and cisplatin-based chemotherapy. Use of endocrine therapy may also be needed to target hormone overproduction and improve quality of life. Tumor size and major blood vessel invasion are independent predictors of long-term survival.³ Prognosis is poor for unresectable or metastatic disease. However, compared to adults, the overall survival is better in younger children.

Given the rarity of ACTs in children, the possible associated genetic syndromes, and the unpredictable behavior in comparison to adults, pediatric patients would benefit from treatment in centers that can offer multidisciplinary expertise in the care of children with adrenal malignancies.

References:

1. Rodriguez-Galindo C, Figueiredo BC, Zambetta GP, and Ribeiro RC. 2005. Biology, clinical characteristics, and management of adrenocortical tumors in children. *Pediatr Blood Cancer* 45(3): 265-73.
2. Masiakos PT, Gerstle JT, Cheang T, Viero S, et al. 2004. Is surgery necessary for incidentally discovered adrenal masses in children. *J Pediatr Surg* 39(5):754-8.
3. Hanna AM, Pham TH, Askegard-Gisemann JR, Grams JM, et al. 2008. Outcome of adrenocortical tumors in children. *J Pediatr Surg* 43(5):843-9.

The Malignant Pheochromocytoma and Paraganglioma Research Group at The University of Texas M.D. Anderson Cancer Center



Camilo Jimenez, M.D., Assistant Professor, Department of Endocrine Neoplasia and Hormonal Disorders

The Malignant Pheochromocytoma and Paraganglioma Research Group at The University of Texas M.D. Anderson Cancer Center features health care providers (endocrinologists, genetic counselors, endocrine surgeons, radiologists, nurses, and nuclear medicine specialists) that work together to understand the behavior of malignant pheochromocytomas and paragangliomas with the ultimate goal to identify effective treatments that can prevent, control, and cure these tumors.

What are pheochromocytomas and paragangliomas?

Pheochromocytomas are tumors that originate in the internal part of adrenal glands in the so-called adrenal medullas. Paragangliomas are tumors that originate in the ganglia of the autonomous nervous system outside of the adrenal glands, meaning they can be located in the head and neck, and the thoracic, abdominal, and pelvic cavities. Because of their origin, pheochromocytomas and paragangliomas may produce hormones called catecholamines (adrenaline and noradrenalin). When these hormones are produced excessively, high blood pressure and palpitations may result, predisposing the patient to cardiovascular disease (heart attacks, strokes, heart failure, arrhythmias, congestion of the lungs, and others). Additionally, the excessive production of catecholamines may induce panic attacks, anxiety, headaches, tremors, and diabetes mellitus.

What are malignant pheochromocytomas and paragangliomas?

Malignant pheochromocytomas and paragangliomas are rare tu-

mors, representing 15% to 30% of all pheochromocytomas and paragangliomas. Different from many other types of cancers, malignant pheochromocytomas and paragangliomas are currently impossible to be differentiated from benign tumors due to their similar histological characteristics. In other words, the cells of both benign and malignant pheochromocytomas and paragangliomas look alike by histological analyses. Consequently, the definition of malignancy relies on their clinical behavior and only the presence of metastases (distant dissemination) and/or a relapse after surgery indicate a malignant nature. Common sites of metastatic disease include lungs, lymph nodes, liver, and bones.

Malignant pheochromocytomas are associated with higher rates of morbidity and mortality due to the tumor growth and its metastatic activity, along with excessive secretion of adrenaline and noradrenalin leading to hypertension and cardiovascular disease. These tumors present a challenge in clinical practice as their behavior is very difficult to predict. In some individuals, malignant pheochromocytomas spread rapidly exhibiting a dramatic and lethal course in a matter of months; in other patients this disease may exhibit a more indolent course over a period of time of years or even decades. Thus, the overall 5-year survival rate may vary from 40-74%.

What are the causes of malignant pheochromocytomas and paragangliomas?

Approximately 50% of patients affected by these tumors carry a hereditary abnormality. Malignant pheochromocytomas and paragangliomas are frequently associated with diseases like the paraganglioma syndrome type 4, less commonly with the paraganglioma syndrome type 1 and von Hippel-Lindau disease, and rarely with the syndromes of neurofibromatosis type 1 and multiple endocrine neoplasia type 2.

Continued on page 9

(Jimenez, continued from page 8)

What is a paraganglioma syndrome type 4?

The paraganglioma syndrome type 4 is caused by mutations that inactivate the gene of the subunit B of the enzyme succinate dehydrogenase (SDHB). This enzyme is a key regulator of the intracellular oxygen metabolism and energy production. Patients who are carriers of SDHB mutations are predisposed to malignant pheochromocytomas and especially malignant paragangliomas in the pelvis, abdomen, and chest. SDHB related malignant pheochromocytomas and paragangliomas exhibit a very aggressive behavior with rapid spread and short survival. SDHB mutations are currently the only clinical recognizable prognosis risk factor in patients with malignant disease. SDHB mutations may be associated with other tumors, i.e., kidney cancer, papillary thyroid carcinoma, and gastrointestinal stromal tumors.

What is a paraganglioma syndrome type 1?

The paraganglioma syndrome type 1 is caused by mutations that inactivate the gene of the subunit D of the enzyme succinate dehydrogenase (SDHD). Patients with paraganglioma syndrome type 1 are predisposed to pheochromocytomas, including especially multiple paragangliomas, but are different from individuals with paraganglioma syndrome type 4. Their susceptibility to develop malignant tumors is much lower.

How are malignant pheochromocytomas and paragangliomas evaluated?

Once the diagnosis of a malignant pheochromocytoma or a malignant paraganglioma is established, a complete biochemical, radiographic, and genetic evaluation must occur. All these studies will help to better delineate the type of disease that a particular individual faces and will help to determine the best treatment modality and follow-up.

Biochemical studies

All patients with malignant pheochromocytomas and paragangliomas have to be evaluated for excessive secretion of catecholamines. Patients need evaluations for plasma and urinary metanephrines and catecholamines and chromogranin A. About 50 % of individuals with these tumors exhibit excessive secretion of these hormones. Individuals with excessive secretion of catecholamines need treatment regimens that antagonize the toxicity of these hormones and/or decrease their production. Thus, effective control of catecholamine toxicity improves hypertension and diabetes mellitus, protects the heart from ischemia (angina, heart attacks), and prevents the appearance of other forms of cardiovascular disease. Additionally, hormonal measurements may be needed as biochemical markers to evaluate the tumor responses to systemic therapies.

Radiographic studies

Patients with malignant pheochromocytomas may need a combination of radiographic studies that delineate the extension of the disease, such as magnetic resonance imaging (MRI) and computerized tomography (CT). MRIs and CTs provide valuable information on the risk to develop complications because of tumor localization and growth, and help to determine if a particular individual exhibits an adequate response to treatment. Functional studies like meta-iodo-benzyl-guanidine scan (MIBG) are very useful in patients whose tumors concentrate MIBG. The MIBG scan helps to evaluate and localize the disease and may indicate if a patient benefits from MIBG as a therapeutic agent. In these order of ideas, patients with MIBG-positive tumors could be considered candidates for treatment with high dosage MIBG. PET/CT scan is another functional study that can identify the disease extension with very much certainty. Perhaps, this radiographic modality could be useful in the follow-up of systemic treatments against these tumors.

Therapy against malignant pheochromocytomas and paragangliomas

The treatment of malignant pheochromocytomas and paragangliomas include medications that prevent complications due to excessive hormone secretion and medications that directly attack the tumor. Medications that control hormone abnormalities include alpha-blockers such as phenoxybenzamine, prazosin, terazosin, doxazosin, beta-blockers like metoprolol, atenolol, propranolol, etc, and medications that decrease the synthesis of catecholamines like methyrosine. These medications used in a medically oriented manner are able to control hypertension and to prevent cardiovascular disease.

For many years very few therapies were available against malignant pheochromocytomas and paragangliomas tumor growth. These therapies include systemic chemotherapy with combination of medications like cyclophosphamide, vincristine, and dacarbazine, and the use of radiopharmaceutical agents like MIBG. Up to one third of patients exhibited good clinical response to these treatments. That response is characterized by the improvement of symptoms, stabilization of disease progression, and hormone secretion improvement. For patients who do not respond to these conventional treatments a new era seems to be beginning. Clinical research with molecules that decrease or prevent the formation the vessels around tumors, drugs that target specific metabolic pathways important for pheochromocytomas survival, and new and more potent radiopharmaceutical agents seems to be approaching.

Our Goal

The malignant pheochromocytoma and paraganglioma research group at The University of Texas M.D. Anderson offers genetic counseling to patients and families, specialized biochemical and radiographic evaluations, systemic therapies, clinical trials, prevention of cardiovascular disease, and a global multidisciplinary evaluation of these rare tumors.

New Systemic Therapies against malignant pheochromocytomas and paragangliomas.

Four recent reports suggest that patients with malignant pheochromocytomas and paragangliomas, some sporadic, some hereditary and associated with von Hippel-Lindau disease, and paraganglioma syndrome type 4 may benefit from blocking the formation of vessels around the tumor. Vascular formation is one of the very early events related to tumor aggressiveness in hereditary pheochromocytomas and paragangliomas. Sunitinib seems to be a promising antiangiogenic medication that warrants further evaluation in clinical trials. A clinical trial proposal is under evaluation.

A multicenter phase II clinical trial with Azedra (MIBG without carrier) is planned to be opened at MDACC pending IRB approval. In previous studies, Azedra has reached 2000 times higher tumor concentrations of MIBG when compared to conventional MIBG. Preliminary results from a phase I clinical trial and observations in animal models and cell cultures suggest that Azedra could be a promising medication against many cases of malignant pheochromocytomas and sympathetic paragangliomas.

International efforts

The seven most important referral centers for malignant pheochromocytomas and paragangliomas around the world including MDACC are sharing their work and experience to develop effective treatments that can cure this disease. The International Malignant Pheochromocytoma Expert Group will meet in New York this May to finalize a clinical trial proposal with a drug that targets a particular molecular pathway that is abnormally active in these tumors. Thus, a new era of hope for patients afflicted by this devastating disease is starting!

Wish to refer a patient to M. D. Anderson?



Online Referrals:

M. D. Anderson has created an online referral process, myMDAnderson, to help you get your patient into M. D. Anderson as quickly as possible. You can use myMDAnderson to follow the treatment your patients receive by viewing transcribed reports and accessing your patients' schedules. To qualify for this free service, you must be a licensed, practicing physician. To start a referral through myMDAnderson, please access this portal: <https://my.mdanderson.org/public/physicians/user/>

Telephone Referrals:

Physician to Physician referrals to the Dept. of Endocrine Neoplasia and H.D., please call 713-792-2841.

To speak to a New Patient Referral Coordinator, please call 713-563-4400.

For Pediatric Referrals (patients less than 18 years of age), please call 713-792-5410

The University of Texas
M. D. Anderson Cancer Center
Endocrine Neoplasia and Hormonal Disorders - Unit 1461
PO Box 301402
Houston, Texas 77230-1402

NONPROFIT
U.S. POSTAGE
PAID
HOUSTON, TX
PERMIT NO. 7052

Announcements

Visit us at Booth #717!



Please come and visit the Dept of Endocrine Neoplasia and H.D.'s exhibit booth at the upcoming AACE (American Association of Clinical Endocrinologists) meeting from May 13-17, 2009 at the George R. Brown Convention Center here in Houston, TX. Come and learn about our cutting edge patient care, research, innovative programs, numerous specialties united under one umbrella and home to one of the largest clinical trial programs in the nation. You'll get to meet with some of our renowned physicians, researchers, and mid-level providers.

Interested in four decades of very unique clinical data gathering? The Atlas of Endocrine Neoplasia book will also be displayed at our booth and also available for a free drawing.

New Thyroid Cancer Survivorship Clinic



The Department of Endocrine Neoplasia and Hormonal Disorders is proud to feature the new Thyroid Cancer Survivorship Clinic at The University of Texas M. D. Anderson Cancer Center. The mission of the Thyroid Cancer Survivorship Program is to address the outcomes of thyroid cancer and its therapy, and improve survivors' health and quality of life through integrated programs in patient care, research, prevention and education.

A Specialty-trained dedicated nurse practitioner and Endocrinologist are here to monitor cancer survivors for recurrence of thyroid cancer. Additionally, our team works closely with other specialized physicians and nurses to look for and manage late effects related to thyroid cancer and its therapies. We are uniquely able to coordinate care related to speech and swallowing problems, bone and heart health, dry mouth, tearing, and dental complications, as well as fatigue.

Finally, an important mission of our Thyroid Cancer Survivorship Program is to ensure that all of our patients are receiving adequate cancer prevention screening for all malignancies, whether at M. D. Anderson or in the community.



To refer a patient, please call our New Patient Referral Coordinators at 713-563-4400.

For physician to physician referrals, please call 713-792-2841.

Department of Endocrine Neoplasia and Hormonal Disorders Faculty

Steven I. Sherman, M.D., Department Chair, Professor
and Center Medical Director, Endocrine Center
Naifa L. Busaidy, M.D., Assistant Professor
Gilbert J. Cote, Ph.D., Professor
Robert F. Gagel, M.D., Professor
Mouhammed A. Habra, M.D., Assistant Professor
Mimi I. Hu, M.D., Assistant Professor

Camilo Jimenez, M.D., Assistant Professor
Victor R. Lavis, M.D., Professor
Sara Peleg, Ph.D., Associate Professor
Rena Vassilopoulou-Sellin, M.D, Clinical Professor
Steven G. Waguespack, M.D., Associate Professor
Sai Ching Jim Yeung, M.D., Ph.D., Associate Professor
Anita K. Ying, M.D., Assistant Professor